

Treatment of FIP in cats with subcutaneous remdesivir followed by oral GS-441524 tablets

Richard Malik DVSc PhD FACVS FASM Centre for Veterinary Education, The University of Sydney

Feline infectious peritonitis (FIP) is an infectious disease of cats, predominantly young cats. It occurs when feline enteric coronavirus multiplying in the intestines undergoes a critical mutation which changes its tissue tropism from enterocytes to macrophages. FIP virus then moves round the body in macrophages – the ultimate Trojan horse mechanism. This leads to a disseminated infection and the development of a fibrinoid necrotising vasculitis and serositis due to deposition of immune complexes consisting of cat antibodies and FIP viral antigens.

Broadly speaking there are two forms of FIP – effusive (‘wet’) FIP and non-effusive (‘dry’) FIP. The actual disease process can occur in the abdominal cavity, the thoracic cavity, pericardium, the eyes, or the central nervous system. Mix and match combinations with different tissues involved, and dry and wet disease, are not unusual.

Until recently, a diagnosis of feline infectious peritonitis (FIP) was a death sentence for a feline patient. But that notion has been turned on its head over the last few years as a result of the pioneering work of Professor Niels C. Pedersen and colleagues at UC Davis.

Over the last 12 months, many vets in Australia have also successfully managed FIP cases using remdesivir and GS-441524.

Omega-interferon (Virbagen) and polyprenyl immunostimulant (PPI) were the first drugs used to treat FIP and both had reasonable efficacy in some patients. Omega interferon was useful in cases of effusive (‘wet’) FIP, often combined with low dose prednisolone according to Ishida’s protocol, whereas PPI, pioneered by Al Legendre, was more useful in cases of non-effusive FIP. In some cases, both drugs were used in concert. The trouble was that both forms of therapy were often expensive especially when both drugs were used, so although patients improved and might have durable clinical remissions while receiving treatment, permanent clinical cures were rare. As a result, most vets still considered a diagnosis of FIP to be a prelude to euthanasia.

That all changed a few years ago because of the culmination of a life-time of FIP research by Pedersen. Niels is an amazing veterinarian, a North American, with Danish heritage. He grew up on a chicken farm and initially wanted to be a large animal clinician, but with great foresight, decided a background in basic science would hold him in good stead. So, soon after graduation, he travelled to Canberra to the John Curtin School of Medical Research at ANU where he undertook an immunology PhD on kidney transplant rejection with Professor Bede Morris in the late 1960s, using sheep as the experimental model to study lymphocyte kinetics.

When Niels returned to UC Davis as clinical faculty, he developed a special focus on infection and immunity. Although he contributed to a huge range of topics in canine and feline internal medicine and genomics, FIP was his favourite disease because of its commonness and also its complexity. His studies extended from the 1980s, when the focus was on diagnosis, virology, and pathogenesis, to the present day, with an increasing focus on therapy.

Working with colleagues at Kansas State University, Niels showed that a purpose-designed protease inhibitor GC-376 could prevent and cure experimental FIP in research cats.^{1,2} Clinical trials in the field using cats with naturally-occurring disease were disappointing, especially when cats had ocular or CNS disease. Not easily defeated, he moved onto a different drug - GS-441524^{3,4} - a nucleoside analogue developed by the North American Pharma Gilead. This molecule proved to be much more effective than GC-376 for treating FIP, both in experimental infections and in spontaneous cases. Starting with pharmacokinetics, and then dose escalation studies using a wide range of clinical cases, Niels and colleagues determined that the dose required depended on whether the patient had dry or wet FIP and whether there was ocular or central nervous system (CNS) involvement.⁵

Surprisingly, Gilead, the manufacturer that developed GS-441524, has so far shown no interest in developing this molecule as a feline drug. So, to fill in the void for effective FIP therapy worldwide, various laboratories in China and eastern Europe started manufacturing GS-441524 and selling it on the black-market.

The widespread availability of GS-441524, often of high quality, and initially very expensive, provided a way for dedicated cat owners to save cats with FIP. Studies by Samantha Evans a clinical pathologist at Ohio State University suggested a cure rate of approximately 80% in the field. Procuring the drug in the recent past was complicated and fraught with issues, which were circumvented at some level by help from various iterations of the Facebook collective ‘FIP Warriors’. Unfortunately for Australian cat lovers, the APVMA and Vet Boards eventually twigged to what was happening, and Border Force made it much more difficult to source GS-441524 and safely import it for veterinary use. Indeed, punitive warnings by the regulatory bodies and vet boards were directed at veterinarians who facilitated the treatment of cats with FIP using black-market drugs.

Ironically, the COVID 19 pandemic provided a novel solution to this problem. Gilead had developed remdesivir (GS-5734) as a drug for treating hepatitis C, Ebola, and human Coronavirus disease. Remdesivir is a prodrug of GS-441524, containing an extra chemical side chain (including a phosphate group) that is supposed to improve intracellular penetration (Figure 1B). Remdesivir (as the product Veklury) was given provisional registration (for two years) by the TGA in July 2020 for treatment of SARS-CoV-2 infections in human COVID-19 patients. This process of registration would normally have taken several years, but the severity of the pandemic expedited the process by relying on preliminary trial data. As remdesivir became a licensed human drug and Gilead licensed manufactures around the world, it has meant there are now more options of quality raw material available. This has circumvented problems with using a drug purchased on the black market, with the allied issues of unknown purity and consistency of product over time.

In 2020, the animal compounding pharmacy **BOVA Australia** secured reliable supplies of remdesivir in a suitable format for IV and subcutaneous administration to cats. Studies in Australia have determined the shelf-life after reconstitution to be in excess of 12 days and confirmed efficacy *in vitro* against Coronaviruses using tissue culture. Drug analytic purity is regularly checked by HPLC. For the past year, veterinarians in every state of Australia have been using remdesivir for the treatment of cats with FIP. There has been a mixture of effusive and non-effusive cases, including some cats with ocular involvement (uveitis) and others with multifocal CNS disease. Based on approximately 500 cats treated between October 2020 and November 2021, remdesivir is proving to be highly effective at managing FIP infections. It is slightly easier to administer subcutaneously and seems a little less painful during injection compared to GS-441524 and does not cause the local injection site reactions seen with injectable GS-441524. Initially, remdesivir was used exclusively in Australia, although for the last 2 months it has also been available in Britain from BOVA UK.

The molecular weight of remdesivir is 603 g/mol, while the molecular weight of GS-441524 is 291 g/mol. This might suggest that cats being treated with remdesivir require approximately twice the dose compared to GS-441524, although this does not account for possibly improved intracellular penetration of remdesivir in certain tissues compared to GS-441524. The suggested dose rate for remdesivir in human patients with COVID19 is a 200 mg loading dose intravenously (IV), followed by 100 mg IV daily. For a 70 kg human patient, this represents a daily dose of 1.3 mg/kg, so using allometric scaling, a dose of 5-10 mg/kg daily for a cat was considered to be in the right ballpark. Our experience over the first 500 cases, however, was that many cats ended up needing a higher dose of remdesivir for permanent cure, and so we have revised our dose recommendations upwards (see later). Remdesivir is provided by BOVA as a 10mg/ml sterile solution ready to use in a 10ml vial.

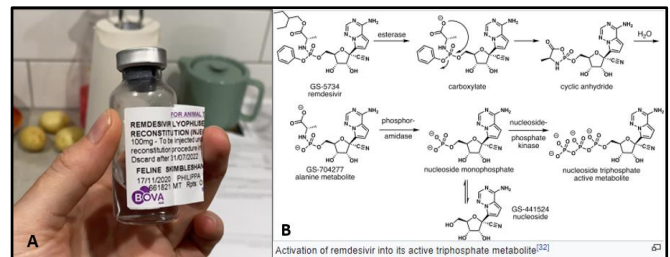


Figure 1. (A) BOVA Remdesivir reconstituted and ready for therapy. Once it is reconstituted, the content of a vial is stable for at least 120 days at 5 °C – and usually a vial is used up in 3-7 days. The vial is best stored refrigerated. (B) The pathway by which remdesivir travels intracellularly to be activated as GS-441524.

Currently, Australia and the UK are the only countries where remdesivir is readily available via prescription for veterinary use. However, veterinarians in India, New Zealand, South Africa, and some parts of Europe, have also started accessing the drug using human suppliers.

Figure 2: Séverine Tasker’s amazingly comprehensive and practical review of the diagnosis of FIP.

Diagnosis

The full differential diagnosis of FIP is beyond the scope of this article, but readers are strongly encouraged to read the superb article by Séverine Tasker in the *Journal of Feline Medicine & Surgery*.⁶

Although FIP can occur in cats of any age, most cases occur in kittens and cats younger than 3 years-of-age. Persistent and often high fever that fails to respond to antibiotic therapy (and often NSAIDs) is a common finding, as is elevated total plasma protein due to increased globulin concentrations (diffuse gammopathy on serum electrophoresis). In effusive or ‘wet’ FIP, the albumin to globulin ratio may drop to < 0.45. Acute phase reactants such as serum amyloid A and α 1-acid glycoprotein tend to be markedly elevated. Many cats with FIP also have secondary immune-mediated haemolytic anaemia, increased AST and ALT activities and icterus.

Diagnostic imaging is critical to a timely diagnosis, and this has been greatly facilitated by adoption of digital radiology and the widespread availability of diagnostic ultrasound in small animal practice. Pleural effusion is readily appreciated from chest X-rays, while abdominal effusion is best detected using ultrasound (Figure 3), especially if you have a range of high frequency transducers. Note that in some cases the fluid pockets can be focal and loculated. Often there is some fluid around the kidney underneath the renal capsule, kittens can have scrotal oedema, while in the odd case the effusion is limited to the pericardial sac. But the key thing is – look for (i) effusion in any body cavity, (ii) granulomas in the kidney, liver, or lungs, (iii) large intra-abdominal and mesenteric lymph nodes (Figure 5) or marked thickening of the iliocaecocolic region ('focal FIP') (Figure 5). Chest radiographs after drainage of pleural effusion can show changes consistent with viral pneumonia.

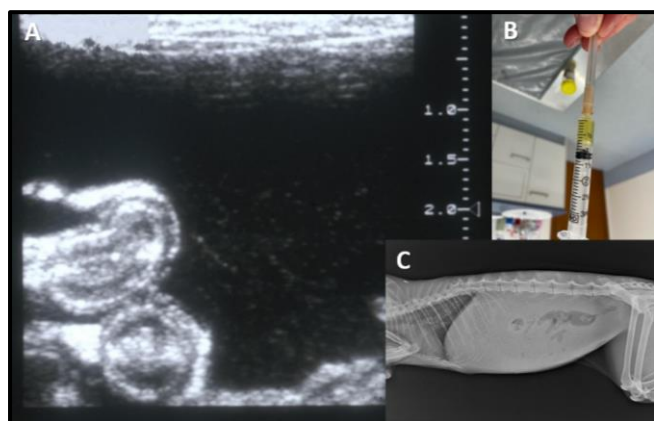


Figure 2: (A) Abdominal ultrasound scan showing abundant highly echogenic fluid (fibrin strands) in a cat with high protein ascites due to effusive FIP. (B) The inset shows the viscid yellow to straw coloured fluid. (C) Ground glass appearance of the abdomen in a plain abdominal radiograph suggesting fluid in the abdomen.

If you see an effusion – tap it – as fluid is the best diagnostic sample.

High protein fluid, often yellow to straw coloured is characteristic (Figure 3B). If you can see a granuloma in an organ, or if large lymph nodes are evident – do an FNA, make a smear, stain with RapidDiff and look for neutrophils and macrophages (pyogranulomatous inflammation) in the absence of visible infectious agents (Figure 4). The two diseases which most often cause confusion in adult cats are lymphoma and some types of lymphocytic cholangitis (associated with high protein ascites).

Effusive disease is obviously much easier to diagnose as ascitic, pericardial or pleural fluid provides a convenient sample which can be examined cytologically and via fluid analysis and then subjected to immunofluorescence (IFA) for FIP antigen or reverse transcriptase PCR to detect FIP nucleic acid. IFA is performed at VPDS, B14, University of Sydney (easily arranged through Vetnostics, QML, ASAP, VetPath,

Gribbles or IDEXX). It is usually cheapest, however, to submit the sample directly to the University laboratory.

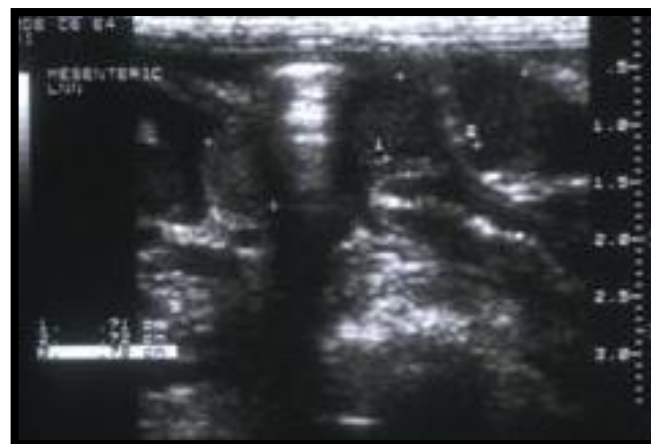


Figure 3: Marked mesenteric lymphadenomegaly in a cat with dry FIP.

Dry FIP is more problematic, as usually it requires a fine needle aspirate biopsy of pyogranulomatous lesions in the liver, kidney, or abdominal lymph nodes. Occasionally, wet FIP cases can paradoxically have fluid specimens which are negative on IFA and/or PCR testing, yet the patient still likely has FIP as reflected by a favourable response to remdesivir or GS-441524 therapy.

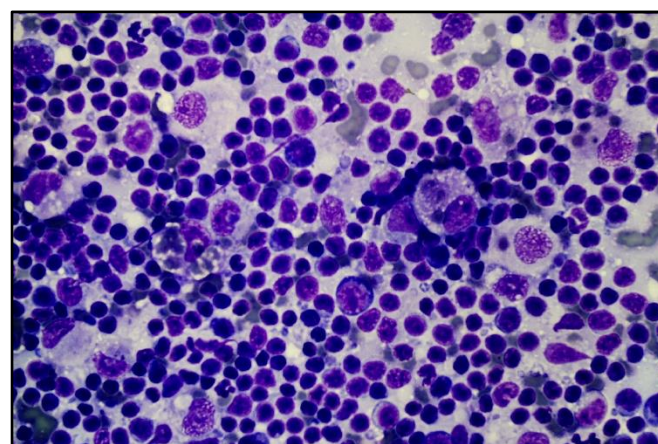


Figure 4: RapidDiff-stained smear of a fine needle aspirate from the mesenteric lymph nodes of a 4-year-old Oriental cat with dry FIP. The prominent macrophages are the key to the cytological diagnosis. Photo supplied by Trish Martin.

Treatment

We have been treating cats with FIP using remdesivir (IV and SCI) since October 2020 and more recently using GS-441524 (orally), so our protocols are constantly evolving with experience. So, far, about 500 cats have been treated. We try to avoid being too prescriptive in our recommendations, as our suspicion is that there is not a single protocol which suits all patients, and every case has unique considerations, including the size of the patient, whether the cat is still 'happy' and eating adequately, or is depressed and

dehydrated. An important consideration is the emotional and financial commitment of the owner. A key feature to mention is that both drugs are very safe, even in sick cats and kittens.

Note the dose recommendations which follow are higher than those initially recommended a year ago. Although lower doses worked in many patients, we found this was often a false economy, as disease recurrence at the end of treatment and development of viral resistance during therapy seems to be related to an insufficient initial dose. So, we have learnt to be more aggressive from the get-go, which in the long term ends up being less expensive (i.e., no requirement for a 2nd course of therapy)

Our greatest experience has been with remdesivir. This drug is expensive, and the owner needs to make a commitment to a costly treatment course that spans a period of 3 months. For most clients, this represents an emotional and financial strain. My view is that in many cases money is better spent on the antiviral therapy *per se* rather than on extensive diagnostics and monitoring.

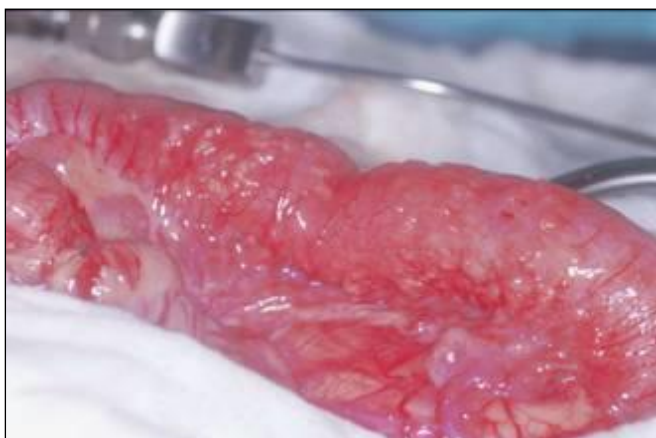

Figure 5: Marked thickening of the iliocaecocolic region of a Devon Rex cat with so called ‘focal FIP’, usually a form of non-effusive FIP. Photo supplied by Penny Tisdall.

One approach in newly diagnosed cats with severe disease, is to hospitalise cats for the first 3-4 days of therapy while remdesivir is given intravenously (IV), effectively as a loading dose. Patients begin their treatment with remdesivir while they are receiving IV fluid therapy (use 2-4 mL/kg/hr; Hartmann’s solution or Plasmalyte on the first day, and subsequently 0.45% NaCl and 2.5% dextrose containing 20 mmol KCl/L). On day 1 of hospitalisation, remdesivir is administered at a high dose intravenously (10-15 mg/kg diluted to 10 mL with saline and given SLOWLY over 20-30 minutes or longer, manually or using a syringe driver; in human patients it is given over 2 hours) to provide a loading dose to fill up the volume of distribution for the drug. This

achieves rapid antiviral efficacy. In cases with CNS disease, we suggest 20 mg/kg as the daily IV dose. Note that many cats can appear somewhat depressed for a few hours after the IV infusion of remdesivir. In human patients, remdesivir may cause infusion-related reactions, including low blood pressure, nausea, vomiting, sweating, or shivering, but we have not observed this in our feline patients.

The benefit of starting therapy intravenously is that dehydration, if present, is corrected, and you have IV access in case you need to administer other drugs (e.g., anticonvulsants, corticosteroids). Importantly, once the IV catheter is secure, daily injections of remdesivir do not cause any pain or discomfort. However, if the cat is eating and is diagnosed at an early stage in the disease course, then IV therapy is not necessary and the same doses can be given subcutaneously – saving a great deal of money.

Cats with FIP treated with remdesivir typically improve markedly over the first 2-3 days. We have observed, however, that effusive cases and especially those that have presented with pleural effusion prior to treatment should be monitored closely, as the combination of the antiviral effect of the remdesivir and greater than maintenance delivery of crystalloids can result in transient worsening of pleural effusion. This necessitates drainage twice daily using a 19-gauge butterfly needle and a 3-way stop-cock (ideally using ultrasound guidance to find the best window for needle insertion). These ‘secondary’ pleural effusions can be fatal if not detected early and seem to occur in about 1 in 10 effusive cases treated with remdesivir.

A further problem occasionally seen at this time is the development of neurological signs, including seizures. Our view is that this is not a drug effect *per se*, but rather the unmasking of subclinical CNS FIP. Such cats need careful observation, while the development of seizures mandates the use of anticonvulsant medication, such as midazolam (0.3 mg/kg IV), alfaxan or propofol (given IV to effect), followed by levetiracetam (Keppra) (10–20 mg/kg, PO every 8 hours). Phenobarbitone is a reliable anticonvulsant, however it has the propensity to increase the metabolism of many drugs, and until we better understand the pharmacokinetics and metabolism of remdesivir and GS-441524, it is probably safer to use levetiracetam in this setting. Some clinicians also administer dexamethasone or prednisolone as a one-off treatment to help settle down the CNS inflammation.

Although we advocate preliminary IV therapy for the sickest FIP patients, cats and kittens that are still ‘happy’, and eating do not require IV therapy at the outset and can instead be started with subcutaneous injections at 10-12 mg/kg/day (20 mg/kg for CNS disease). This, of course, is far less expensive as the cats or kittens do not need to be placed on an infusion pump and kept in hospital, a stressful environment. With clients who have financial constraints, this might be preferable way to begin therapy. Some clever colleagues, like Jim Euclid, have developed a hybrid approach where kittens receive subcutaneous fluids as a bolus daily and remdesivir is injected into the fluid ‘lump’.

Subsequently, cats were given ONGOING subcutaneous injections of remdesivir. Initially, this was for 84 days, and such cases represented the bulk of cases we have treated to date. More recently, we have been using aggressive IV/SCI remdesivir for preliminary therapy, and then cats are transitioned onto oral GS-441524 for 10 weeks of consolidation therapy.

After initially using lower doses, which did not succeed in every patient, we now use the following treatment protocols, as follows:

- i. for cats with wet FIP: 10-12 mg/kg once daily (SID) for 2 weeks
- ii. for cats with prominent ocular involvement: 15 mg/kg SID by subcutaneous injection (SCI) for 2 weeks; cats with severe uveitis should be also given topical corticosteroids (Pred Forte or Maxidex) for 2-3 days (no longer!) and atropine eye ointment
- iii. for cats with neurological FIP with CNS signs: give 20 mg/kg SID SCI for 2-4 weeks.⁵

It is important that owners are counselled properly on how to optimally administer daily injections. Cats will find the injection less painful if the remdesivir solution in the syringe is allowed to come to room temperature rather than be injected when cold from the fridge. Furthermore, teaching them simple tasks such as using a new needle when injecting the cat (i.e., use a different needle to the one used to withdraw the drug from the vial) and using 21 or 23-gauge needles, will make injections more tolerable. Even though 21-gauge needles are larger, possibly the ability to inject more quickly gives them an advantage in some cats. Alternately, veterinarians might prepare a full weeks' worth of injections for the owner, to make things simple and sterile, in a box to be kept in the fridge, with a new syringe to be used every day.

In cats that continue to find the SC injections painful, we have used gabapentin orally (50 to 100 mg per cat) and/or transmucosal or SC buprenorphine administered 30-60 min prior to the injection for sedation/analgesia. The area to be injected can also be clipped so that topical EMLA cream can be applied 30 minutes prior to injection. BOVA manufacture a faster acting local anaesthetic gel which might be useful in some patients. In exceptional cases, we have placed a new cephalic catheter every 4-5 days to allow owners to give IV therapy rather than SC injections. The injection site reactions which have been reported with INJECTIBLE GS-441524 overseas do not seem to occur with remdesivir.

After 2-4 weeks of remdesivir, and after fluid in the abdomen has disappeared, and ocular and CNS signs improved or resolved, we now suggest a change to GS-441524 tablets. This is done for 3 reasons (i) it reduces costs (ii) it eliminates painful SC injections (iii) in some patients, it is more effective. Remdesivir injections are probably more reliable than oral GS-441524, and in the worst cases you might elect to give them for 4 weeks, but for most cats 2 weeks is sufficient, and the convenience and lower cost of the oral formulation trumps everything else.

The use of GS-441524 tablets is comparatively new to Australia but has been used widely overseas (see <https://sockfip.org/fip-treatment-with-oral-formulations-of-gs-441524/>). Usually, the recommended ORAL dose of GS-441524 is just the same as the dose of SCI/IV remdesivir: wet FIP cases get 10-12 mg/kg PO SID, ocular cases 15 mg/kg PO SID and CNS cases 20 mg/kg (or higher), although we tend to err on the side of more rather than less, as GS-441524 is more cost effective and is even safer than remdesivir. In CNS cases, where large doses are being given, it's probably best to give 10 mg/kg PO every 12 hours (BID), to circumvent the ceiling effect said to limit absorption of large doses.

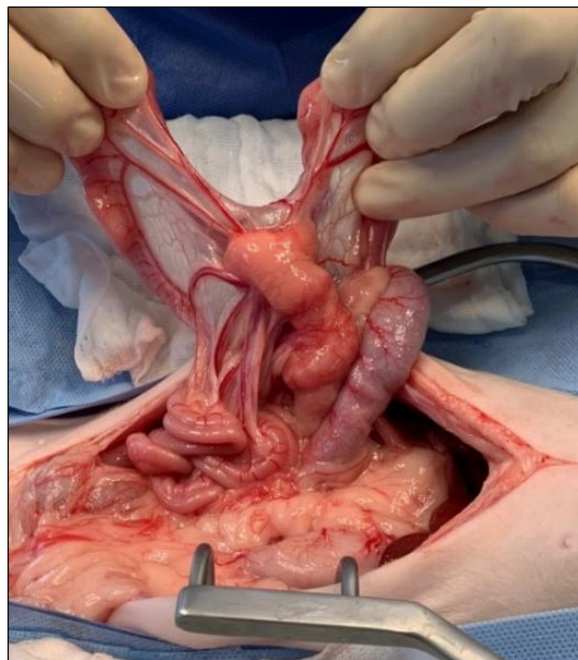

Figure 6. Focal dry FIP, with pyogranulomatous inflammation of intraabdominal lymph nodes. Rather than undertaking an exploratory laparotomy, lymph node biopsy, histology and immunohistology, it might be more cost effective, where there is a high suspicion of FIP, to trial 3 days of IV remdesivir therapy. A FNA of the enlarged lymph node is probably the ideal diagnostic option for practitioners with this skillset.

Why are the doses roughly the same? On a mg/kg basis, GS-441524 has twice as many active molecules as remdesivir (because of the difference in their molecular weight), but the bioavailability of GS-441524 is perhaps 50% (only half what is given is absorbed, and this is affected by feeding and also by a ceiling dose effect) - so the two considerations cancel out.

We suggest that the GS-441524 tablets are given with a very small treat e.g., Dine creamy treats (to make sure the pill goes down), with the main meal given 1 hour later. The tablets provided by BOVA are Tuna flavoured 50 mg tablets that are quad-scored so they can be halved or even quartered.

In situations when owners cannot afford a full course of therapy, we have used mefloquine (Lariam; 5 mg/kg orally once daily compounded into capsules or 62.5 mg twice weekly) after preliminary remdesivir/GS-441524 therapy.

Mefloquine has been shown to have an antiviral effect by Phillip McDonagh, Jacqui Norris, Merran Govendir and colleagues at the Sydney School of Veterinary Science.⁷ This probably occurs by mefloquine usurping biochemical intracellular pathways utilised by FIP virus, a mechanism that has recently been shown also for the anti-leprosy drug clofazimine,⁸ and several other drugs. In several cats where owners were unable to afford a full course of remdesivir, mefloquine has seemed effective in getting the cats across the line to achieve clinical cure.

The main advantage of buying remdesivir and GS-441524 from BOVA for treating FIP cases is that the products we are using is subjected to quality assurance. It is only a matter of writing a prescription with the client's name and address, the name of the patient and the dose to be administered, and the compounder can usually provide vials or tablets to any veterinarian in Australia within 24-48 hours.

Currently, the cost of a 100 mg vial of remdesivir is \$250 plus GST and postage (\$280 typically at the practice). The cost of GS-441524 tablets is a pack of 10 tablets for \$600 plus postage and handling. Of course, buying multiple vials and tablets at one time reduces postage and handling fees. We believe most owners will feel much more comfortable obtaining a product from a well-known Australian company, rather than sending money overseas and hoping that black-market drugs of unknown quality will make it to Australia safely without being seized by customs.



Figure 7: BOVA Australia 's Gs-441524 tablets. They are tuna flavoured. And can be divided into halves or even quarters. MUCH EASIER than injections for most cats. Less stress and less expense.

There is no reason what-so-ever why a well-motivated veterinarian should not be able to manage these cases in their own practice. This is often more convenient to the owner, especially if they struggle with the daily injections and need a practice that is close and convenient.

Veterinarians wishing to explore this option, or with general questions about FIP case management, can e-mail Sally Coggins (dr.sallyc@gmail.com), Richard Malik (richard.malik@sydney.edu.au), David Hughes (concordvets@concordvets.com.au), Gretta Howard (drgretta@gmail.com), or Professor Jacqui Norris (jacqui.norris@sydney.edu.au), for advice in relation to diagnosis or therapy. Many Australian veterinarians with an interest in FIP have developed considerable expertise in the management of these cases. For example, Andrew Spanner in Adelaide has treated in excess of 20 cases with excellent results. Feline clinicians, cat only practices and many internal medicine specialists have managed cases and so for vets who are hesitant in treating their own cases, they have the option of referral.

Clinicians that have accepted FIP case referrals from general practitioners include but are not limited to: QLD Rhett Marshall, Marcus Gunew, Alison Jukes, Rachel Korman; NSW Katherine Briscoe, Michael Linton, Randolph Baral, Melissa Catt; VIC - Carolyn O'Brien, Keshuan Chow, Amy Lingard; WA-Martine Van Boeijen and Murdoch University Veterinary Teaching Hospital; TAS Moira van Dorsselaer.

All these clinicians (and likely more we are not aware of) are happy to accept cases for diagnostic work- up and therapy. They are all probably happy to discuss management of cases with you.

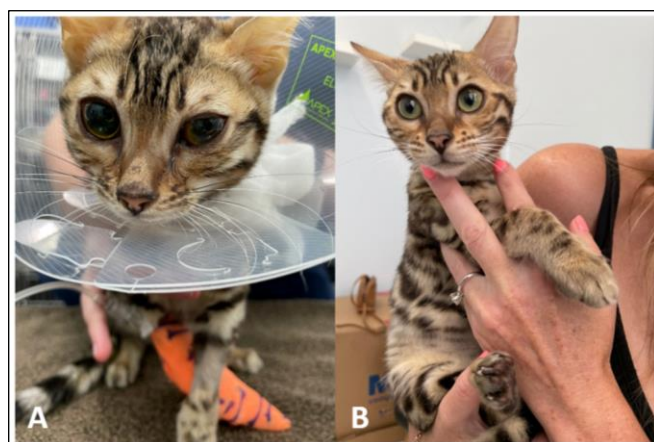

Figure 8: Bengal kitten with CNS and ocular FIP (A: before) and (B: after) after Remdesivir. This cat also had pulmonary granulomas.

Sally Coggins, working with Lara Boland, Emily Pritchard, Associate Professor Mary Thompson, and Professor Jacqui Norris at Sydney School of Veterinary Science will be interested in treating cases with comprehensive diagnosis and monitoring provided *gratis*. This will form part of Sally's PhD program, so you will be helping her progress her studies by referring cases. As a result of these studies, hopefully we will develop have a better idea of how quickly the cats respond and exactly when therapy can be safely discontinued. Owners will still need to purchase remdesivir and GS-441524 for therapy. This group also has an interest in treating cases with interferon-omega and mefloquine.

Most FIP cases do very well with GS- 441524 or remdesivir therapy. Niels Pedersen has assembled an amazing resource for veterinarians interested in managing FIP cases - <https://sockfip.org/dr-pedersen-research/>. The website is pure gold. Some recommendations are provided on how to monitor cats during therapy. I am not very protocol driven, so for me the key things to monitor are appetite, attitude, level of activity and changes on body weight and condition over time. Most clinicians like to monitor haematology and serum biochemistry every month to ensure that all measurable abnormalities are improving, although this can be stressful for the patient and add to the cost of therapy. A compromise is to collect a few drops of blood to monitor PCV, total plasma protein (TPP) using refractometry and the colour of plasma – in that way one can determine if anaemia is improving, icterus is resolving and whether the reduction on gamma globulin concentrations is resulting in a lower TPP.

Do not be concerned by transient increases in globulin concentrations during early therapy; when high protein effusions are absorbed, lots of extra immunoglobulins are dumped into the patient's plasma. This can be common even up to week 8 of treatment but resolves by week 12.

What about the kitten with multifocal CNS disease, where CNS FIP is the most likely cause of the clinical signs? The traditional approach is serology (to try to exclude cryptococcosis and toxoplasmosis), a good dietary history and trial of thiamine to rule out vitamin B1 deficiency, then MRI scans (Figure 8) and a CSF tap for fluid analysis and multiplex neuro-qPCR analysis). This approach is very expensive and there is also a finite risk from the anaesthesia and especially CSF collection. We have found that 3-5 days of IV or SC remdesivir therapy can be used as a therapeutic trial in cats with likely CNS FIP and is a cost-effective alternative to the full diagnostic work-up which might cost \$3-5,000, or more.

Likewise, if the choice is an exploratory laparotomy, biopsy of abnormal tissues, histology, and immunohistochemistry for FIP antigen to diagnose dry intraabdominal FIP *versus* a 3–5-day trial of remdesivir or GS-441524, the drug trial might be considered to be better option in terms of both welfare and reduced cost. In most cats with non-effusive FIP – there is a prompt improvement with antiviral therapy, with normalisation of fever, improvement in appetite and better overall attitude within 2 to 3 days. If the patient fails to respond to antiviral therapy, then of course exploratory laparotomy and biopsy of representative organs is sensible, as the major DDx are lymphoma and lymphocytic cholangitis.

This is a matter of every clinician's personal style. A FNA for cytological and sometimes immunohistochemical assessment or PCR is cogent non-invasive option where this expertise is available, but sometimes this does not give a definitive answer. Some veterinarians insist on getting a tissue diagnosis and positive immunohistology or PCR in every patient, while others are keen to 'treat for the treatable' with a 3–5-day trial of remdesivir/GS-441524, and then proceed to ex lap if there is no unambiguous response to therapy.

It is incredibly satisfying to see cats and kittens that are unwell turn the corner and become normal. It really is something that lifts your spirits as a clinician. It is good science and good veterinary medicine!

Conclusions

In the past, a diagnosis of FIP was an intellectual exercise, so we could end a cat or kitten's suffering with the certainty of an accurate diagnosis. Now, because of Niels Pedersen life-time studies of FIP, we are in a position to successfully treat perhaps 80% or more of cats with FIP, if the client has sufficient finances. It's too early to say how many of these will later recur.

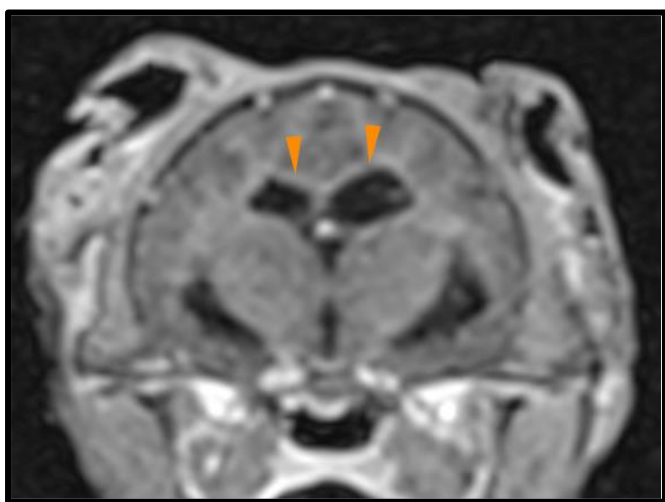


Figure 9: An MR image in the transverse plane post contrast with T1 weighting. Note: the dilation of the lateral ventricles with very mild enhancement of the ependymal lining (orange arrows). Image courtesy of Christine Thomas.

There is a huge learning curve to the diagnosis and management of cases, but with effort, a good GP vet should be able to work with a diligent owner towards obtaining a clinical cure. The most important thing is to not place too many obstacles in the way of a committed owner, and to support them through the 12-week marathon treatment course, by helping them find the best way to medicate their patient. This might involve a sedative/analgesic regimen to help make the cat more tractable and prevent discomfort, having the client bring their cat to the clinic daily for remdesivir injections, or swapping to GS-441524 tablets when the stress of injections is just too much for the owner. It is also important to manage hiccups along the way and perhaps providing a payment plan that will let the treatment be affordable for a committed client.

Finally, the impact of COVID-19 on coronavirus research has been profound, and there are several very promising drugs in development such as molnupiravir from Merck and another oral drug from Pfizer.

EXECUTIVE SUMMARY

2 stage approach to therapy

Stage 1 - INDUCTION

IV/SC Remdesivir injections

For cats with wet FIP: 10-12 mg/kg remdesivir by subcutaneous injection (SCI) once daily (SID) for 2 weeks

For cats with ocular involvement: 15 mg/kg SID remdesivir SCI for 2 weeks

For cats with neurological FIP and CNS signs: remdesivir 20 mg/kg SID for 2 weeks

Stage 2 - CONSOLIDATION

After 2 weeks of injectable remdesivir, swap to GS-441524 tablets

For cats with wet FIP: 10-12 mg/kg GS-441524 orally SID for 10 weeks

For cats with ocular involvement: 15 mg/kg SID GS-441524 orally SID for 10 weeks

For cats with neurological FIP and CNS signs: GS-441524 10 mg/kg orally BID (20 mg/kg/day) for 10 weeks

References

1. Kim, Y.; Liu, H.; Galasiti Kankanamalage, A.C.; Weerasekara, S.; Hua, D.H.; Groutas, W.C.; Chang, K.O.; Pedersen, N.C. Reversal of the progression of fatal coronavirus infection in cats by a broad-spectrum coronavirus protease inhibitor. *PLoS Pathog.* 2016, 12, e1005531.
2. Pedersen, N.C.; Kim, Y.; Liu, H.; Galasiti Kankanamalage, A.C.; Eckstrand, C.; Groutas, W.C.; Bannasch, M.; Meadows, J.M.; Chang, K.O. Efficacy of a 3C-like protease inhibitor in treating various forms of acquired feline infectious peritonitis. *J. Feline Med. Surg.* 2018, 20, 378–392.
3. Murphy, B.G.; Perron, M.; Murakami, E.; Bauer, K.; Park, Y.; Eckstrand, C.; Liepnieks, M.; Pedersen, N.C. The nucleoside analog GS-441524 strongly inhibits feline infectious peritonitis (FIP) virus in tissue culture and experimental cat infection studies. *Vet. Microbiol.* 2018, 219, 226–233.
4. Pedersen, N.C.; Perron, M.; Bannasch, M.; Montgomery, E.; Murakami, E.; Liepnieks, M.; Liu, H. Efficacy, and safety of the nucleoside analog GS-441524 for treatment of cats with naturally occurring feline infectious peritonitis. *J. Feline Med. Surg.* 2019, 21, 271–281.
5. Dickinson PJ, Bannasch M, Thomasy SM, et al. Antiviral treatment using the adenosine nucleoside analogue GS-441524 in cats with clinically diagnosed neurological feline infectious peritonitis. *Journal of Veterinary Internal Medicine.* 2020. doi: 10.1111/jvim.15780.
6. Tasker S. Diagnosis of feline infectious peritonitis: Update on evidence supporting available tests. *Journal of Feline Medicine and Surgery.* 2018;20(3):228-243. doi:10.1177/1098612X18758592
7. McDonagh, P.; Sheehy, P.A.; Norris, J.M. Identification, and characterisation of small molecule inhibitors of feline coronavirus replication. *Vet. Microbiol.* 2014, 174, 438–447.
8. Yuan, S., Yin, X., Meng, X. *et al.* Clofazimine broadly inhibits coronaviruses including SARS-CoV-2. *Nature* (2021). <https://doi.org/10.1038/s41586-021-03431-4>
9. <https://sockfip.org/> - the BEST resource on the internet or anywhere for FIP.




Figure 10: Two cat with dry FIP after successful therapy. As a keen young vet told me by e-mail not so long ago – “this is why I did vet science!”

Costings:

2 kg kitten with wet FIP

4 100 mg vials remdesivir - \$1000

35 50 mg tablets GS-441524 - \$2100

Handling and GST - \$30 plus \$310 = \$340

Total \$3440 about \$290 a week for 12 weeks

4 kg cat with dry FIP

7 100 mg vials remdesivir - \$1750

70 50 mg tablets GS-441524 - \$4200

Handling and GST \$30 plus \$600

Total \$6550 about \$545 per week for 12 weeks




Figure 11: Two littermates which both developed FIP and both of whom were successfully treated with remdesivir and GS-441524.