

A synopsis of feline infectious peritonitis virus infection

Niels C Pedersen, D.V.M., Ph.D., Center for Companion Animal Health, Room 213, CCAH Bldg., School of Veterinary Medicine, University of California, Davis, CA, 95616, USA.
Tel:+1-530-752-7402, Fax:+1-752-7701; E-mail: ncpedersen@ucdavis.edu

Introduction

This synopsis is taken from a much larger and more scientifically comprehensive review of FIP literature from the period 1963 through 2008. Although more technical than the Q&A format review also provided on the SOCKFIP website, it should prove helpful to those people with the desire to obtain more in depth knowledge of this disease. It is also hoped that the inclusion of references will demonstrate the amount of actual peer-reviewed research that has been done on the disease and to make readers aware of the actual state of FIP prevention, diagnosis and treatment. Readers will be also less apt to rely on the mass of anecdotal and frequently incorrect information on FIP that floods the web.

Historical

Feline infectious peritonitis (FIP) was first described as an “important disorder of cats” by [Holzworth \(1963\)](#) at the Angell Memorial Animal Hospital, Boston and a clinico-pathologic conference on this disorder from this same institution was published the following year ([Feldman and Jortner, 1964](#)). The disease was thought to be infectious but no specific etiologic agent was identified at the time. [Wolfe and Griesemer \(1966\)](#) were the first to propose that FIP was caused by a virus. [Zook et al \(1968\)](#) observed virus particles in the tissues of experimentally infected cats, but were unable to characterize the agent. Ward (1970) recognized the close similarities of FIP virus (FIPV) in tissues to members of the family *Coronaviridae*. [Montali and Strandberg \(1972\)](#) were the first to report that FIPV infection could be either granulomatous (dry, parenchymatous) or effusive (wet, non-parenchymatous). The close genetic relationship of FIPV to coronaviruses of dogs and swine was first reported by [Pedersen et al \(1978\)](#). A cause and effect relationship between a common feline enteric coronavirus (FECV) infection and FIP was first reported by [Pedersen and coworkers \(1981b\)](#). The realization that FIPV is a simple and relatively common mutant form of FECV was first demonstrated by [Vennema et al \(1998\)](#).

Following its appearance, FIP incidence steadily increased and it is currently one of the leading infectious causes of death among young cats from shelters and catteries. The reason for the sudden emergence of FIP is not known, but there are at least three possible explanations. First, coronaviruses may have speciated into cats within the last half century. It is noteworthy that FIP appeared within a decade of the initial descriptions of transmissible gastroenteritis (TGE) of pigs in North America ([Haelterman 1962](#)). The causative virus of FIP is closely related to TGEV of pigs and canine coronavirus (CCV) ([Pedersen et al 1978](#)), although they are still genetically distinguishable ([Motokawa et al 1996](#)). However, recombinants between these three viruses are known to occur ([\[Benetka et al 2006\]](#), [\[Herrewegh et al 1998\]](#), [\[Pedersen et al 1984\]](#) and [\[Wesley 1999\]](#)). At least one strain of canine coronavirus can induce mild enteritis in cats and enhance a subsequent infection with FIPV, indicating a special closeness to feline coronaviruses ([McArdle et al 1992](#)). Therefore, CCV may be a more likely parent of FECV in this scenario. A second explanation may involve a dramatic but more subtle genetic change in the strains of FECV that predominated in the cat population from the 1960's onward. As will be explained below, the virus that causes FIP is a simple mutation of the ubiquitous and not very noteworthy FECV. The strains of FECV that existed before the appearance of FIP may have been resistant to the FIP mutation. A third possibility involves changes in how cats were viewed as pets and their husbandry in this modern era. There was a dramatic shift in the status, keeping, and breeding of cats as pets after WWII. The numbers of pet cats greatly increased, purebreeding and cattery rearing became increasingly popular, and more cats, and in particular kittens, found themselves in shelters. These large multiple cat indoor environments are known to favor feline enteric coronavirus (FECV) infection and FIP ([reviewed by Pedersen et al 2008](#)). Interestingly, feline leukemia virus (FeLV) infection also became rampant among indoor multiple cat households during this period, and FeLV infection was a significant cofactor for FIP until it was pushed back into nature with testing, elimination/isolation, and eventual vaccination in the 1970s and 1980s ([Weijer et al 1986](#)).

Causative agent

Feline infectious peritonitis virus (FIPV) is a mutant form (biotype) of FECV ([\[Pedersen et al 1981b\]](#), [\[Poland et al 1996\]](#) and [\[Vennema et al 1998\]](#)). Therefore, one cannot understand FIP and FIPV without understanding FECV infection. FECV is a ubiquitous coronavirus infection of cats. It is found worldwide and up to 40-80% of cats may be shedding the virus in their feces at any given point in time ([Reviewed by Pedersen et al 2008](#)). The virus is passed by the fecal-oral route and can survive for up to two weeks in litter dust. It is easily passed from one premise to another on people's bodies and clothing. FECV infection is largely asymptomatic, causing a transient vomiting and mild diarrhea in a proportion of cats. This enteric infection is rarely fatal in its own right. Cats may shed the virus for many years,

stop shedding after 6-9 months or so, or shed intermittently. Some cats that have recovered from the infection can be reinfected, even with the same strain of FECV and their pattern of shedding will resemble that of a primary infection.

The mutation responsible for the FIPV biotype is consistently found in one of the 11 or more genes that make up the FECV genome, the 3c gene. The mutations are usually single nucleotide polymorphisms (SNPs) or nucleotide deletions that inactivate all or parts of the gene, thus preventing the production of a normal 3c protein. The specific deleterious mutation in 3c is specific for each individual cat that develops FIP, even when affected kittens are from the same litter ([Vennema et al 1998](#); [NC Pedersen, UC Davis, 2009, manuscript in preparation](#)). This explains why FIP cats do not seem to be infectious for other cats. If cat-to-cat transmission existed, FIPV isolates from cats involved in the same outbreaks would have identical 3c gene mutations. Loss of 3c gene function does not prevent replication of the mutant (i.e., FIPV) *in vivo* or *in vitro*, but is thought to drastically alter cell tropism by enhancing its internalization and replication in macrophages ([Dewerchin et al 2005](#)) and [Rottier et al 2005](#)). In contrast, the parent FECV preferentially infects a very narrow cell type, the mature cells that are found at the tips of the intestinal villi ([Pedersen et al 1981b](#)).

The FECV→FIPV mutation is more likely to occur during primary infection and in kittens, because both conditions lead to a higher level of FECV replication ([Pedersen et al 2008](#)). The higher the replication rate, the more likely mutations will occur. Very young cats also have a decreased resistance to the mutation once it occurs ([Pedersen et al. 2008](#)). FIPV mutants occurred in 20% of primary FECV infected cats in one study ([Poland et al 1996](#)). However, FECV infection is often recurrent and there is some evidence that FIP may also occur as a consequence of these recurrent bouts of virus replication. [Addie et al \(1995\)](#) followed 56 cats deemed to have recurrent FECV infections based on decreasing and rising antibody titers; 3 of these 56 animals subsequently developed FIP.

Epizootiology

FIP occurs wherever FECV is found ([\[Addie et al 1995\]](#), [\[Foley et al 1997a\]](#) and [\[Pedersen et al 1981b, 1983a,b\]](#)) and is therefore worldwide and ubiquitous among virtually all cat populations. FECV particularly endemic in multi-cat populations, such as catteries, shelters and homes with numerous cats. It is made worse by a constant influx of new cats, especially younger cats and kittens. FECV is also very prevalent among urban homeless cats. One third of older cats and 90% of kittens and juveniles presented to shelters in Sacramento, CA, USA were shedding FECV at the time of entry ([Pedersen et al 2004](#)). A

significant proportion of these cats were from the feral population, so it is fair to say that FECV is enzootic among both indoor and outdoor cat populations. Similar findings have been reported for most, but not all, other countries. [Bell et al \(2006a,b\)](#) found the seroprevalence of FECV to be 34% among pedigree cats in the Sydney area and non-existent in feral cats tested.

Extensive studies have been done on both natural ([\[Addie et al 2001\]](#), [\[Foley et al 1976b\]](#) and [\[Pedersen et al 1981b\]](#)) and experimental FECV infections ([\[Pedersen et al 1981b\]](#) and [\[Pedersen et al 2008\]](#)). Shedding has been shown to occur from the ileum, colon and rectum ([Herrewegh et al 1997](#)). The same strain tends to persist in all cats within a given cattery or region; however, an occasional cat in a group may be infected with more than one strain or a different strain ([Addie et al 2001](#)). Virus shedding is somewhat associated with coronavirus antibody titer levels; groups of cats with indirect fluorescent antibody titers of $\geq 1:100$ or much more likely to have coronavirus shedders than groups of cats with titers $\leq 1:25$ ([Pedersen et al 2008](#)).

Most deaths from FIP occur in cats 3-16 months of age and are uncommon after 3-5 years ([\[Pedersen 1976a\]](#) and [\[Pedersen 1983a\]](#)). FIP was the most common single cause of disease in cats younger than two years of age in one study, while cancer was the most common single disorder in the 2-8 year age range ([Marioni-Henry et al 2004](#)). The incidence of FIP among a veterinary medical teaching hospital from 1986-1995 was 1:200 among new feline visits, 1:300 among total cat accessions, and 1 of 100 accessions at diagnostic laboratories ([Rohrbach et al 2001](#)). The incidence of FIP is significantly higher among kittens and younger cats originating from pure breed catteries and shelters. An average of 1-5% of young cattery or shelter cats in the US will die from FIP, with losses in catteries higher than from shelters. Enzootics with $>10\%$ mortality were noted at least once in five years among young cats and kittens originating from four typical catteries that were studied ([Foley et al 1997a](#)). [Cave et al \(2002\)](#) studied the causes of death among 274 sheltered and privately owned pedigreed and non-pedigreed kittens from 1986-2000. Twenty-five per cent of all kitten mortality was due to feline parvovirus (FPV). The main viral infections in 15-38 day olds were feline herpesvirus and feline calicivirus. Feline infectious peritonitis caused the death of 17/203 kittens in the postweaning (35-112 days of age) period, with an incidence of 8.4%.

FIP losses occur as enzootics or epizootics, with the former being more common. FIP losses are sporadic, unpredictable and infrequent in the enzootic form; catteries with enzootic FIP may not have any deaths for years, followed by several cases in rapid succession. The disease may then disappear, only to reappear months or years later. Overall mortality from enzootic disease over a 5 year or more periods is usually 1-5%. However, epizootics of 3-

49% have been observed in groups of kittens raised in one cattery over a 4 year period and similar explosive outbreaks have been seen in several other catteries ([[Pedersen 1983a](#)] and [[Potkay et al 1974](#)]). Epizootics of FIP seldom last for more than 6-12 months before returning to an enzootic state. Enzootic FIP is usually associated with persistence of the same or similar strains of enteric coronaviruses within a population, while epizootics are multifactorial and reflect increased population stresses, usually associated with overcrowding and high kitten production; the unintentional use of genetically predisposed breeders; possible bouts of horizontal transmission, or the introduction of a new strain of FECV.

Several risk factors for FIP have been identified in catteries ([Foley et al 1997a](#)). FIP in this study was not significantly associated with particular catteries, mean cat number, mean age, gender, cattery median coronavirus antibody titer, husbandry and quarantine practices, caging and breeding practices, or prevalence of concurrent diseases. However, individual cat age, individual cat coronavirus titer, overall frequency of fecal coronavirus shedding, and the proportion of cats in the cattery that were chronic FECV shedders, were associated with increased risk of FIP. Deaths from FIP were more frequent in fall and winter, and on the basis of analysis of cattery records, the number of deaths varied yearly. Epizootics (> 10% mortality rate) were reported at least once in 5 years among the 4 catteries studied. One of the most significant factors appeared to be genetic susceptibility, which accounts for up to 50% of the incidence ([Foley and Pedersen 1996](#)). Multi-cat households that have not personally experienced FIP losses, but which relocated or sold cats that later develop FIP, were no more likely to experience FIP over a 6 year period than households that had experienced no prior FIP losses or catteries that had lost cats to FIP ([Addie et al 1995](#)). Thus, every cattery with enzootic FECV infection is at risk of losing cats from FIP if they breed enough kittens over a long enough time. The risk of developing FIP appears to decrease over periods of 3 years in groups of cats, indicating an increase in population resistance ([Addie et al 1995](#)).

The incidence of FIP in shelters seems to be directly correlated with the numbers and density of young cats and the length of time that they are held before adoption; greater and longer being much worse ([K. Hurley, UC Davis, unpublished findings, 2008](#)). Reports from the US and Europe indicate an increased risk for young cats, purebreds, and intact males and a decreased risk in spayed females ([Rohrbach et al 2001](#)). A report of 42 confirmed FIP cases from Australia between 1990 and 2002 has shown FIP to be over-represented in certain pure breeds (Burmese, Australian Mist, British Shorthair and Cornish Rex) and under-represented in other breeds (Domestic shorthair, Persian) and a more even distribution across the age spectrum ([Norris et al 2005](#)). The breed incidence of another veterinary teaching hospital was determined over a 16-year period and the breed, gender

and reproductive status of affected cats were compared to the general cat population and to mixed breed cats evaluated during the same period ([Pesteanu-Somogyi et al 2006](#)). As with previous studies, sexually intact cats and purebred cats were significantly more likely to be diagnosed with FIP; males and young cats also had a higher prevalence of disease. Abyssinians, Bengals, Birman, Himalayans, Ragdolls and Rexes had a significantly higher risk, whereas Burmese, Exotic Shorthairs, Manx, Persians, Russian Blues and Siamese cats were at decreased risk. Such studies indicate that the incidence of FIP among breeds can vary greatly between countries and regions and FIP losses are probably more related to bloodlines within a breed than to breeds themselves.

Clinical Features

Feline infectious peritonitis is mainly a disease of domestic cats. It has also been recognized in the African lion, Mountain lion, Leopard, Cheetah, Jaguar, Lynx, Serval, Caracal, European wild cat, Sand cat and Pallas cat ([\[Colby and Low 1970\]](#), [\[Colly 1973\]](#), [\[Fowler 1978\]](#), [\[Juan-Sallés et al 1998\]](#), [\[Pedersen 1983a\]](#), [\[Pfeifer et al 1983\]](#), [\[Poelma et al 1974\]](#), [\[Theobald 1978\]](#), [\[Tuch et al 1974\]](#) and [\[Watt et al 1993\]](#)). An almost identical infectious peritonitis has been described in interferon gamma deficient mice ([\[France et al 1999\]](#) and [\[Kyuwa et al 1998a,b\]](#)) and in ferrets ([\[Martinez et al 2008\]](#)) infected with their respective species of coronavirus.

Feline infectious peritonitis refers to the more common effusive (wet, non-parenchymatous) form of the disease; a transmissible inflammatory condition of the visceral serosa and omentum with exudation into the abdomen ([\[Wolfe and Griesemer 1966\]](#)). A second form of the disease is characterized by granulomatous involvement of parenchymatous organs such as the kidneys, mesenteric lymph nodes, bowel wall, liver, central nervous system and the eyes ([\[Montali and Strandberg 1972\]](#) and [\[Pedersen 1976a\]](#)). Granulomatous FIP is called "dry", parenchymatous, or noneffusive because there is no inflammatory exudation into body cavities.

The most common form of FIP is wet or effusive, although the proportion of cats with dry FIP appears to be rising over the last few decades. Cats rarely manifest both forms of the disease at the same time, and if they do, it is usually a transition stage from wet to dry or dry to wet. Under experimental conditions, cats that develop dry FIP often have a brief episode of effusive disease at the onset, while some cats with dry FIP may become more effusive in the terminal stages of their illness. However, these transitions are much less noticeable in nature.

The incubation period (time from infection to disease) of effusive FIP is 2-14 days under experimental conditions ([[Evermann et al 1981](#)], [[Pedersen and Black 1983](#)], [[Pedersen and Floyd 1985](#)] and [[Pedersen et al 1981a](#)]). The incubation period for experimentally induced dry FIP is several weeks longer. However, the actual incubation period in natural infections is unknown, but there is evidence the infection may smolder in a subclinical state for weeks, months and even years before overt signs are noticed. In retrospect, the clinical onset of FIP may be preceded by a long history of vague ill health and stunted growth. Co-infections with other feline pathogens may lower resistance to FIPV or may complicate the disease picture (see proceeding discussion).

The earliest signs of overt FIP, besides a failure to thrive in young cats, include a progressively worsening malaise, fluctuating fever, inappetance, and weight loss. Other signs of disease are superimposed on these basic disease signs, depending on the form and organ distribution of the inflammation (Table 1). Abdominal distension is the most common physical finding in wet FIP and ranks higher than cardiovascular disease, neoplasia, hepatic disease, and renal disease as causes of ascites in cats (Wright et al 1999) (Fig. 1). The abdomen, besides being greatly enlarged, is often doughy feeling and painless on palpation, and a fluid wave is easily induced on percussion. Upon opening, the abdomen is found to contain up to a liter of a yellow-tinged, slight to moderately cloudy, mucinous fluid (Fig. 2). Dyspnea can be a feature of cats with pleural involvement and thoracic effusions (Table 1). Clinical signs due to ocular and central nervous system involvement are seen in less than 9% of cat with the wet form of FIP (Table 1).

There are several uncommon features of effusive FIP that warrant mention. Intact males frequently develop scrotal enlargement due to extension of the peritonitis to the tunics surrounding the testes and edema (Fig 1). A syndrome of hepatic lipidosis and extreme skin fragility has been described in one cat with wet FIP ([Trotman et al 2007](#)). In-utero FIPV infections have been observed in kittens born to queens that developed effusive FIP during pregnancy; pneumonia, pleuritis and hepatitis were the principal lesions in affected kittens ([McKiernan et al 1981](#)). Many cats with FIP have a generalized inflammation of the joint linings (synovitis), due to immune complexing or the migration of infected macrophage/monocytes into the synovial membrane. A cat with FIP may present, therefore, with signs of fever and lameness. This can be mistaken for another type of infection or an immune mediated polyarthritis. However, the more classical signs of FIP usually develop soon after, making the cause of the lameness apparent.

As the name “dry FIP” implies, thoracic and abdominal effusions are either absent or too scant to be detected other than at necropsy. Involvement of the eyes and/or CNS predominates in 60% of the cats with dry FIP (Table 2). Signs referable to abdominal

Table 1. Variability in clinical signs of effusive (wet) FIP

Clinical signs referable to	
<u>Involvement of the:</u>	<u>% of affected cats</u>
Peritoneal cavity	58.0
Peritoneal and pleural cavity	22.0
Pleural cavity	11.0
Peritoneal cavity and eyes	2.8
Peritoneal cavity and CNS	1.9
Peritoneal and pleural cavity, CNS	0.9
Peritoneal and pleural cavity, eyes	0.9
Pleural cavity, CNS and eyes	0.9
Peritoneal cavity, CNS, eyes	0.9

involvement are seen in 40% of animals, either with or without ocular and CNS disease (Table 2). The abdominal lesions of dry FIP are much larger, fewer in number and less widespread than the lesions of wet FIP. Lesions of dry FIP tend to extend downward from the serosal or pleural surfaces into underlying parenchyma; hence the alternative name “parenchymatous FIP.” Abdominal lesions are frequently found in the kidneys (Fig. 3) and mesenteric lymph nodes (Fig. 4, 5), and somewhat less frequently in the liver and hepatic lymph nodes. Involvement of the wall of the caecum and colon with associated caeco-colic lymphadenopathy is a specific form of dry FIP (Fig. 6) associated with signs typical of an ulcerative colitis (i.e., soft, blood and mucus laden stools) ([Harvey et al 1996] and [VanKruiningen 1983]). Abdominal lesions are often evident on palpation and sometimes associated with local pain. About 10% of cats with dry FIP will have thoracic involvement, but chest lesions are usually localized and only one part of a more systemic infection. Small granulomas may involve the pleura and underlying lung parenchyma (Fig. 7). Involvement of the pericardium has been described, and can lead to fluid distention of the pericardial sac, cardiac tamponade and heart failure (deMadron 1986).

Central nervous system involvement is frequent in cats with dry FIP (Table 2). Over one half of cats with inflammatory disease of the CNS have FIP, as well as one sixth of the total number of cats showing CNS signs from any cause (Bradshaw et al 2004). FIP is also the most common disease of the spinal cord in cats less than 2 years of age and is one of the three leading causes, along with lymphosarcoma and vertebral neoplasia, of spinal disease among cats of all ages (Marioni-Henry et al 2004). Most cats with CNS FIP are less than 2 years of age and often originate from large multiple cat households (Foley et al 1998).

Central nervous system involvement in cats with dry FIP is varied in its clinical expression, dependent on what other organs are involved (Table 2), its exact localization in the nervous system, and severity. Signs referable to spinal cord involvement, such as posterior paresis, incoordination, hyperesthesia, seizures and palsy of the brachial, trigeminal, facial and sciatic nerves, have all been reported ([Holliday 1971], [Kornegay 1978], [Legendre and

Fig. 1. Grossly distended abdomen of a kitten with effusive feline infectious peritonitis. Note the scrotal enlargement due to inflammation of the tunics.

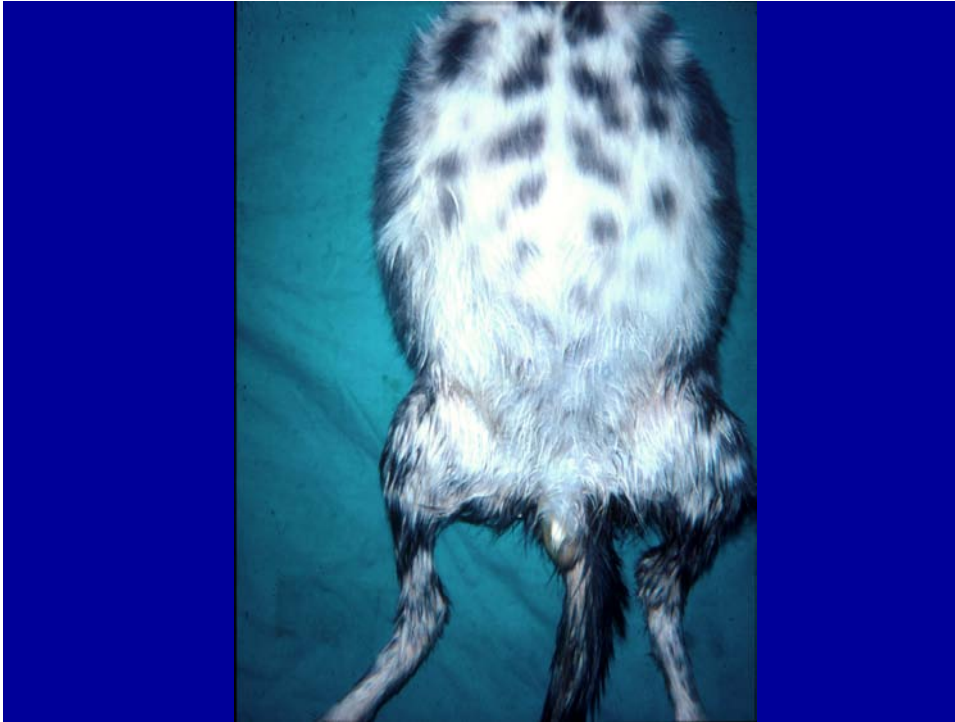

Fig. 2. Over 600 ml of a yellow, mucinous effusion was removed from the abdomen at necropsy. Note fibrin tags on liver and spleen and ground glass appearance of the serosa.

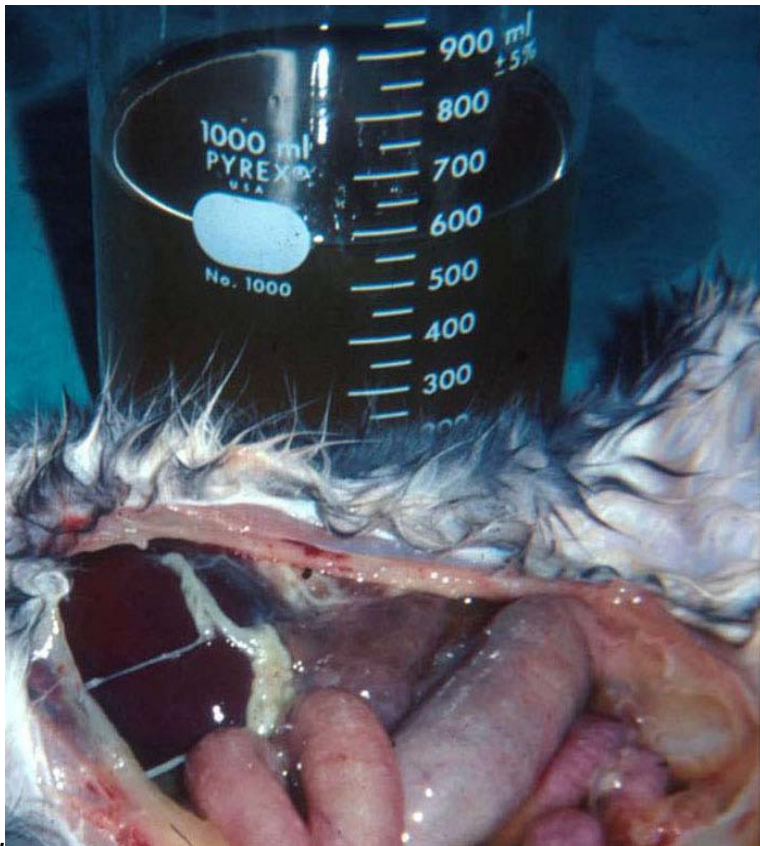

Fig. 3. Cross section of a kidney from a cat with dry FIP. Numerous granulomatous lesions are seen on the capsule of the kidney and extending downward into the parenchyma.

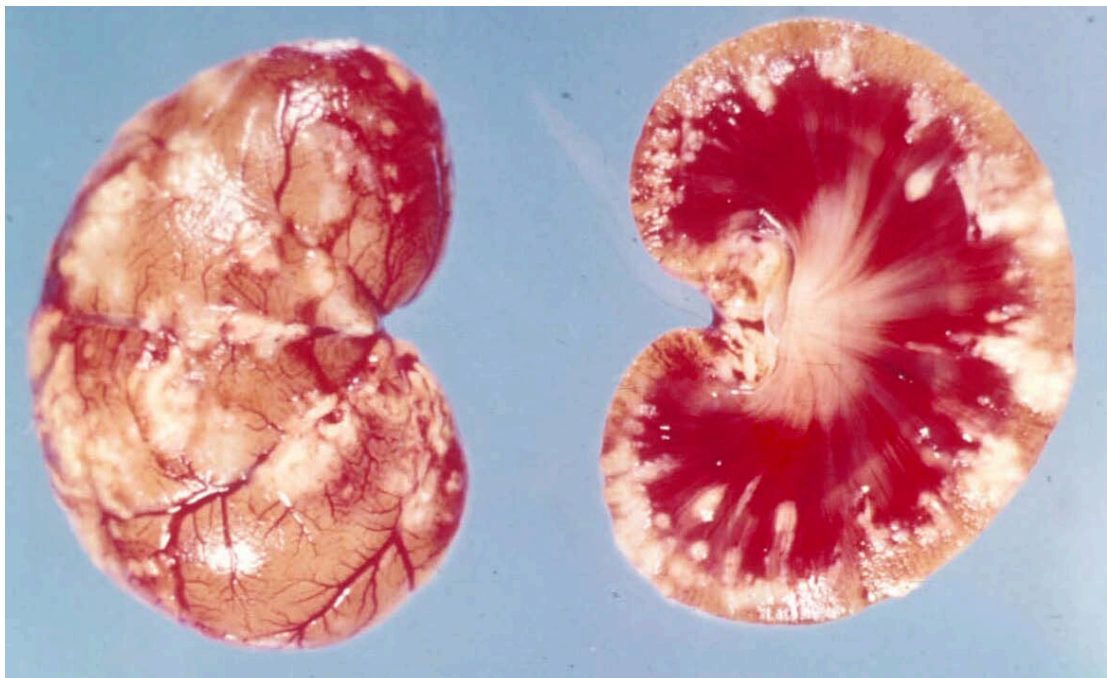

Fig. 4. Enlarged mesenteric lymph node in a cat with the dry form of FIP. Note the residual fibrinous plaque on the spleen. Such residual lesions support the concept that many cases of dry FIP began as a brief bout of wet FIP.

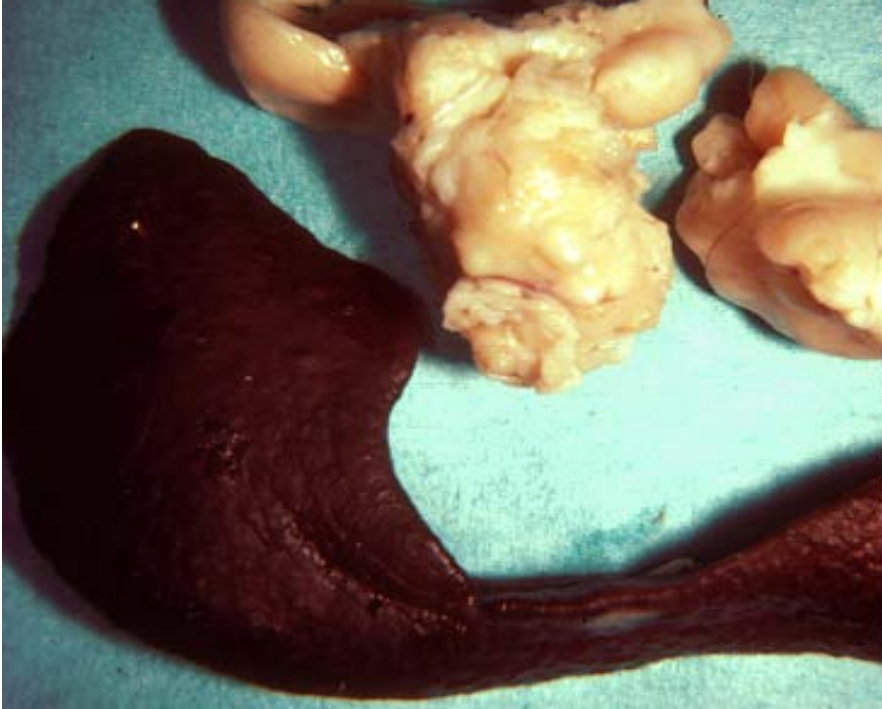


Fig. 5. Mesenteric and hepatic lymph nodes and liver from a cat with nonfusible feline infectious peritonitis. The lymph nodes are enlarged and involved with granulomatous adenitis. The liver capsule contains raised, whitish foci 0.5-1 cm in diameter, extending into the underlying parenchyma.

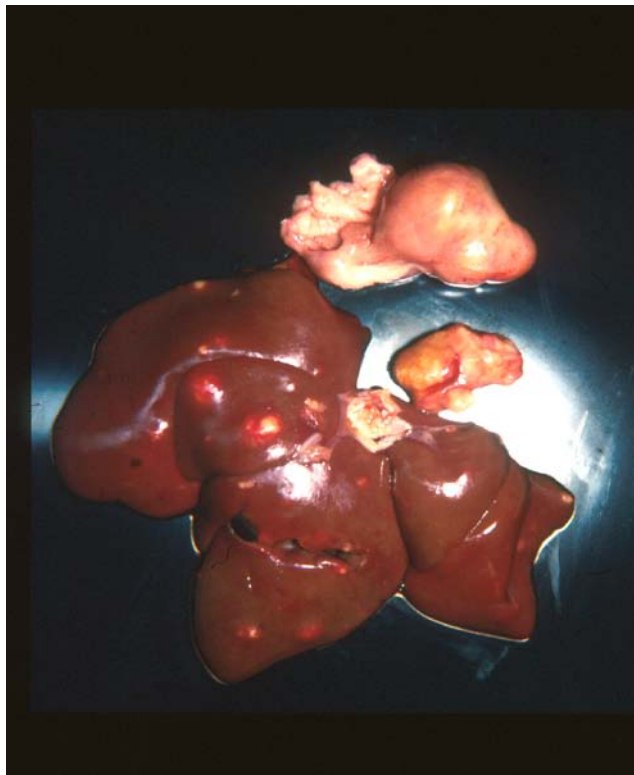

Fig. 6. – Gross appearance of the caecum, colon and ceco-colic lymph nodes of a cat with the intestinal form of dry FIP.

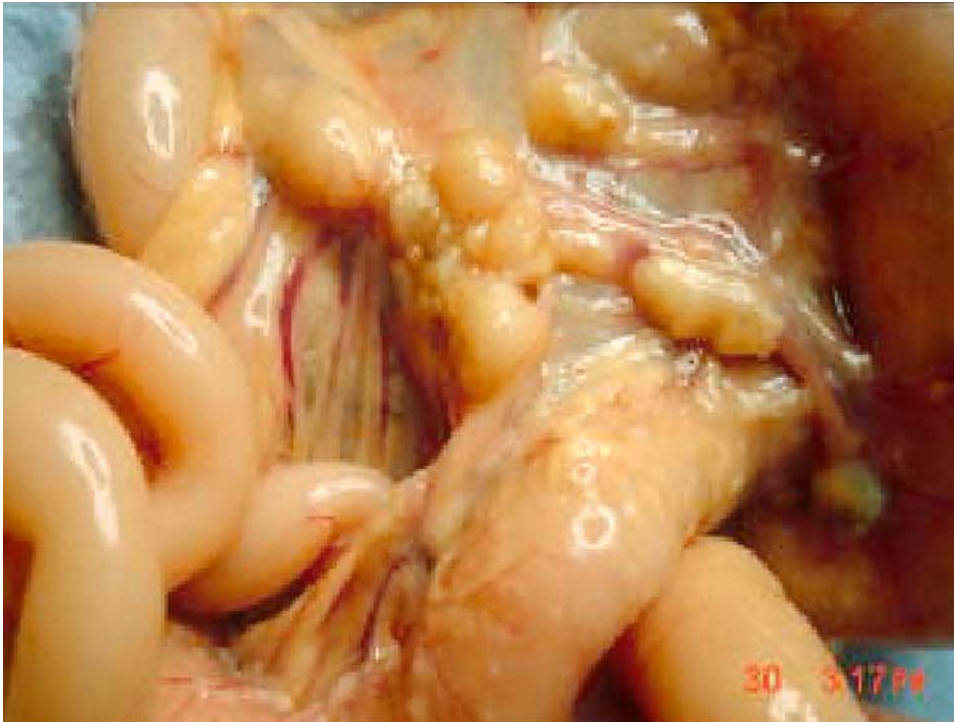


Fig. 7. Lungs and heart of above cat shown in Figure 5. A solitary pleural granuloma is noted along the edge of a cranial lung lobe.

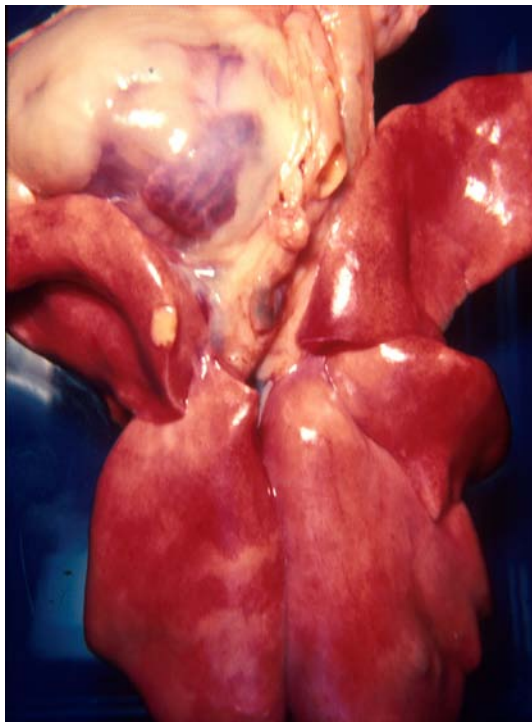


Table 2. Variability in clinical signs of non-effusive (dry) FIP.

Clinical Signs Referable to	
<u>Involvement of:</u>	<u>% of affected cats:</u>
Peritoneal cavity	32.0
CNS	23.0
Eyes	15.0
CNS and eyes	8.5
Peritoneal cavity and eyes	7.4
Peritoneal and pleural cavities	4.3
Peritoneal and pleural cavities, CNS	3.2
Peritoneal and pleural cavities, eyes	2.1
Peritoneal cavity, CNS, eyes	2.1
Pleural cavity	1.1
Pleural cavity, CNS, eyes	1.1

Whitenack 1975], [Marioni-Henry et al 2005], [Pedersen 1976a]. [Slauson and Finn 1972], [Quesnel et al 1997] and [Timmann et al 2007]). Hydrocephalus, secondary to disease of the choroid and ependyma, has also been documented ([Fankhauser and Fatzer 1977], [Hayashi et al 1980], [Krum et al 1975] and [Foley et al 1998]) and can lead to dementia, personality changes (aggression, rage, hiding/withdrawal, etc.) or convulsive disorders. Cerebellar-vestibular signs, such as nystagmus, head tilt or circling, have also been caused by FIP.

Eye involvement, like CNS disease, is much more likely to occur in cats with dry than wet FIP (Tables 1, 2). Uveitis and chorioretinitis are the predominant ocular manifestations of dry FIP ([Campbell and Reed 1975], [Campbell and Schiessl 1978], [Doherty 1971], [Gelatt 1973], [Gillespie and Scott 1973] and [Slauson and Finn 1972]) (Figs 8, 9). FIP is also the most frequent cause of uveitis/chorioretinitis in cats, with less common causes being FeLV-associated lymphosarcoma; trauma; and lens-induced uveitis ([Goodhead 1996] and [Peffer and Wilcock 1991]). Ocular disease in dry FIP occurs solely or in association with lesions in the CNS or peritoneal cavity (Table 2). A change in the coloration of the iris is a frequent early sign of ocular FIP (Fig. 8). Keratic precipitates on the back side of the cornea are characteristic of FIP and are due to accumulations of fibrin, macrophages, and other inflammatory cells (Fig. 9). Focal lesions akin to the granulomas of parenchymatous organs may be apparent in the iris and distort the shape of the pupil (Figs. 8, 9).

There are several uncommon, but interesting, manifestations of dry FIP. Granulomatous involvement of the peripheral tissues resulted in priapism in a castrated cat (Rota et al 2007). Chronic fibrinous and necrotizing orchitis may cause the scrotum and testicles to appear enlarged ([Foster et al 1996] and [Sigurdardóttir et al 2001]) and scrotal enlargement may be one of the primary presenting complaints. Miscellaneous sites for lesions in noneffusive FIP include the nasal passages, tongue and distal small intestine. Syringomyelia has been caused by involvement of the fourth ventricle in one cat (Kitagawa et al 2007). Cutaneous lesions of a granulomatous type have been reported in a FIV infected cat with FIP; the lesions were thought to be due to a coronavirus induced vasculitis (Cannon et al 2005). Toxic epidermal necrolysis has also been observed in a cat with dry FIP (NC Pedersen, UC Davis, unpublished observation 2008). Non-puritic, slightly raised intradermal papules over the neck and chest walls were observed in the terminal stages of a cat that had non-effusive, progressing to effusive, FIP (Declercq et al 2008). FIPV was identified in skin lesions by immunohistochemistry.

Fig. 8. Uveitis of the right eye in a cat with the dry form of FIP. The color of the iris has changed, the anterior chamber is somewhat hazy, and there is a pigmented lesion in the center of the cornea (a keratic precipitate). Note the irregularity in the shape of the right pupil compared to the normal left pupil.

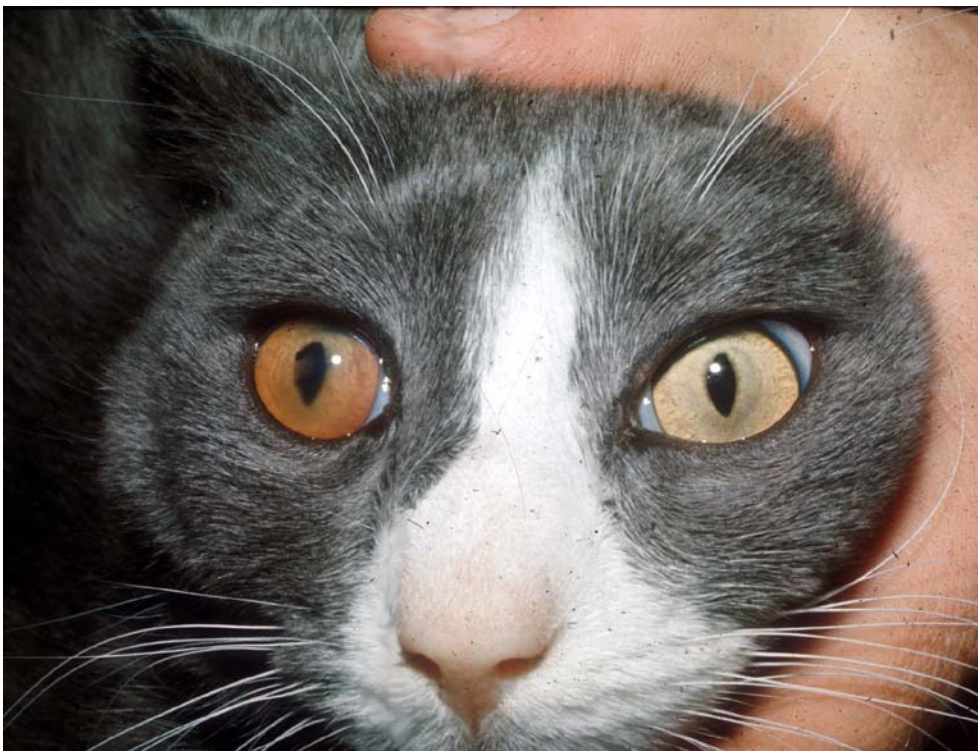
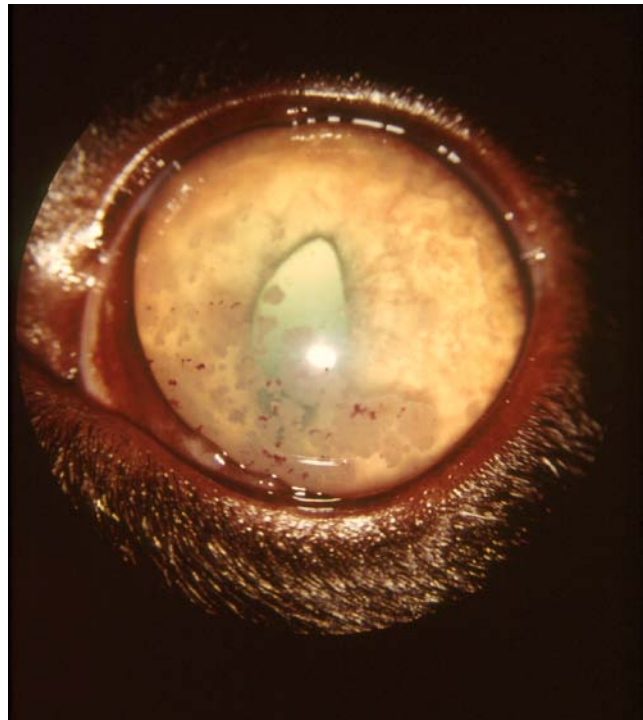


Fig. 9. Keratic precipitates on the inner cornea of a cat with dry feline infectious peritonitis. Note the reversed D-shape of pupil due to infiltration of the iris.



The lesions of dry FIP have also been mistaken for cancer, in particular lymphoma ([Kipar et al 1999] and [Kornegay 1978]). One FeLV negative cat with FIP subsequently developed a myeloproliferative disease (Madewell et al., 1978). Monoclonal gammopathies have been observed in four cats with FIP (MacEwen and Hurvitz 1977) and a fifth cat with FIP was observed to convert from a polyclonal- to monoclonal-gammopathy (Hurvitz 1982, as quoted in Pedersen 1987).

FIP has many interesting interactions with other infectious agents. These agents may affect immunity to FIPV, such as FeLV infection. Alternatively, FIPV may induce an immunosuppression that encourages opportunistic type pathogens. Concurrent FeLV infection was seen in one-third to one-half of all FIP cases that were tested in the 1970s and 1980s ([Cotter et al 1973] and [Pedersen 1976a]). FeLV infection seems to have a specific interfering effect on the ongoing immunity to FIPV. Cats that failed to develop FIP after experimental infection developed FIP within 6-16 weeks after becoming FeLV viremic, indicating that many FIP recovered cats maintain residual infections (Pedersen 1987a). Mimicking the situation in the field, FIP also appears after natural exposure to both viruses ([Pedersen, 1987a] and [Pedersen et al 1977]). With the virtual elimination of FeLV from pet cat populations in Westernized countries, this relationship has become much less common.

Affected kittens with subclinical or clinical FIP are more susceptible to upper respiratory infections caused by mycoplasma, Chlamydomphila or herpesvirus, indicating that their resistance is not normal. It is also known that cats with advanced feline immunodeficiency virus (FIV) infection are more susceptible to FIP when exposed to FECV (Poland et al 1996). Systemic toxoplasmosis, a relatively rare clinical infection of cats, has been described in two cats with FIP. One report was from 1966 (Ward and Pedersen 1966) and a second report from 1995 (Toomey et al 1995). The occurrence of systemic toxoplasmosis in these two cats was probably associated with reactivation of encysted organisms left from a much earlier self-limiting infection. FIP is frequently associated with a lymphopenia, which is indicative of immunosuppression. We have also noticed an increase in bacterial infections in cats with FIP, some manifested as terminal sepsis or more chronic local infections of internal Organs (NC Pedersen and P Pesavento, UC Davis, unpublished observations 2008). One young cat had a chronic bacterial infection of the reproductive tract that was manifested early as a purulent vaginal discharge and terminally as a supportive infection of the ovary and fallopian tube, while a second cat had a secondary bacterial pneumonia. The stresses of pregnancy and parturition, surgical procedures such as spaying, neutering and declawing have also increased the incidence of FIP in young cats, suggesting that stresses occurring at a time when the young cats are fighting an FIPV infection may tip the balance against the host (Pedersen 1976a).

Hematologic, clinicopathologic and imaging Features

The diagnosis of FIP should be relatively simple, given its affinity for younger cats, its strong tendency to involve catteries and shelters, the typical physical and historical findings, and numerous characteristic laboratory abnormalities. Nonetheless, it somehow remains one of the most difficult of diagnoses for many veterinarians. The truth is that veterinarians have little trouble in placing FIP high, or at the top, of their diagnostic list, but have great difficulty, and even reluctance, in confirming their diagnosis. However, it is not only the veterinarian that has difficulties, but the owners as well are reluctant to give up without a definitive diagnosis. It must be remembered that a diagnosis can be based on cumulative odds rather than a single, simple, definitive test result. A young cat from a cattery or shelter with chronic uveitis and/or neurologic signs, high serum proteins, hyperglobulinemia and hypoalbuminemia, fluctuating antibiotic unresponsive fever, leukocytosis with a lymphopenia, and an anemia of chronic disease can have no other disease than dry FIP based on odds alone. Likewise, the same cat with similar history and laboratory findings, but with a yellow-tinged, mucinous, inflammatory ascites instead of uveitis or neurologic signs is highly unlikely to have any other disease than wet FIP. Results from a test that is incorrectly touted as being definitive or highly indicative of FIP will only confuse the issue and induce doubt when the diagnosis should not have been in doubt. Ultimately, FIP must be diagnosed

by applying a workable knowledge of the disease with sensible weighing of signalment, history, clinical signs, clinicopathologic findings, serology and ante- or postmortem examination of affected tissues by histopathology and immunohistochemistry.

Hemograms of cats with FIP often demonstrate several abnormalities, which tend to be similar regardless of the form of disease. A low-grade to moderately non-responsive anemia with hypoalbuminemia is typical of chronic disease. Other common hematologic changes include a leukocytosis with an absolute lymphopenia and neutrophilia, and hyperproteinaemia ([Paltrinieri et al 1998], [Paltrinieri et al 2001], [Pedersen 1976a] and [Sparkes et al 1991]). Serum total protein elevations are associated with increased levels of globulin and decreased levels of albumin. Cats with virus positive lymph nodes at necropsy were purportedly more likely to have globulin elevations (Paltrinieri et al 2001).

Hypergammaglobulinemia is not directly related to feline coronavirus antibody titers (Paltrinieri et al 1998), suggesting that non-specific antibody globulins and/or complement factors are important contributors to the globulin elevation. An albumin globulin ratio <0.6 is considered diagnostic for an inflammatory process, and most commonly FIP (Hirschberger et al 1995). The most consistent changes shown by serum protein electrophoresis were increases in alpha 2- and gamma-globulins ([Paltrinieri et al 1998], [Pedersen 1976a] and [Sparkes et al 1991]). Haptoglobin makes up most of the increase in alpha-2 globulins (Harvey and Gaskin 1978).

Abdominal and pleural effusions of FIP have characteristics that are as definitive as any other single test. Almost one half of all effusions in cats are due to FIP (Hirschberger et al 1995); therefore the odds of FIP are 50:50 by the presence of an effusion alone. If the effusion have the features of FIP the odds are even greater; if the cat is younger the odds are greater still, if the cat is from a shelter or cattery, the odds go up even more, etc. FIP effusions are usually a light to dark yellow, and occasionally green-tinged, due to elevated levels of bilirubin or biliverdin, respectively. The fluid is mucinous in character and when a drop on a slide is touched with a needle tip and then pulled away, a string will often form. The fluid ranges from somewhat clear to cloudy and often contains visible fibrin tags. The protein content of the effusions ranges from 3.9 to 9.8 mg/ul with the globulins comprising 50 to 82 per cent of the total (Sparkes et al 1991). Cell counts can range from 1600 to 25,000 per ul. Macrophages, non-toxic neutrophils and lymphocytes predominate. Fluid effusions, particularly from the pleural cavity, may be tinged with red cells. Effusions will often form partial clots when allowed to sit in an anticoagulant free tube. The electrophoretic pattern of the effusions will be similar to that of the corresponding serum (Paltrinieri et al 1998).

Antibody titers higher than those of the corresponding serum have often been detected in the effusions (Paltrinieri et al 1998), but like comparative antibody titers in serum and CSF, ([Boettcher et al 2007] and [Foley et al 1998]), the significance of this finding has not been

determined. A definitive diagnosis can be made by direct immunohistochemical examination of cells in the fluid for viral antigens (Paltrinieri et al 1998,1999). Immunofluorescence is several times more sensitive than immunoperoxidase. Real time RT-PCR analysis of cells from FIP effusions will demonstrate high levels of viral RNA.

Hyperbilirubinemia, and less commonly hyperbiliverdinemia, frequently without jaundice, are common in cats with FIP, especially the effusive form. In fact, FIP is the most common cause of an icteric serum or plasma in a cat <3 years of age. The urine is also yellow-tinged due to a hyperbilirubinuria. A greenish cast to the urine and serum is less common and due to high levels of biliverdin. The increased level of bilirubin or biliverdin in the blood is usually not due to liver involvement *per se*, but rather to microhemorrhage into tissues and extravascular destruction of red blood cells by phagocytic cells, as part of the vasculitis and disseminated intravascular coagulopathy (DIC). Heme from destroyed red cells is then recycled as biliverdin and finally bilirubin. Cats are deficient in carrier systems to remove these hemoglobin breakdown products from the blood, hence their tendency to accumulate in effusions, lesions, or serum.

Aqueous humor and CSF in cats with ocular or CNS disease also show similar, but more variable, increases in proteins and leukocytes. Typical CSF findings in cats with FIP include a protein concentration of greater than 200 mg/dL and a white cell count of over 100 cells/ μ L, consisting predominantly of neutrophils (Rand et al 1994). In contrast, the CSF of cats with other viral disease usually has a protein concentration of less than 100 mg/dL and a total white cell count of less than 50 cells/ μ L. Singh et al (2005) defined an inflammatory CSF as having a total nucleated cell count greater than 5 cells/ μ L, or one in which the total count was normal but differential count was abnormal. Gender, degree of CSF inflammation, neuroanatomical location and systemic signs provided were not helpful in determining whether the inflammation was due to FIP or other diseases such as Cryptococcus, lymphoma or trauma. Synovial fluid from cats with effusive FIP is frequently inflammatory in character.

Many serum antibody tests have been used for the diagnosis of FIP, including indirect immunofluorescent antibody (IFA), virus neutralization, and ELISA ([Barlough et al 1982] and [Pedersen 1976c] and [Pratelli 2008]). Some feel that ELISA is the most sensitive procedure (Pratelli 2008), but this author feels that most antibody tests are equivalent if done properly. The most common test is an IFA assay using TGEV (Kummrow et al 2005) or FIPV (Pedersen 1976c) infected swine or cat cells as a substrate. Titers are usually read in distinct multiples of serum dilutions (1:5, 1:25, 1:100, 1:400, 1:1600, 1:6400). They were originally reported as being helpful in diagnosing cats that had FIP or were suffering from other illnesses (Pedersen 1976c). Unfortunately, coronavirus antibodies do not differentiate

between cats infected with FECV and FIPV, and although very high titers ($\geq 1:1600$) are highly suggestive of FIP and negative titers tend to rule out FIP ([Hirschberger et al 1995] and [Pedersen 1976c]), the overlap in titers between healthy coronavirus exposed and diseased cats is so great that it has little definitive diagnostic value in individual animals ([Pedersen 1983a,b], [Paltrinieri et al 1998] and [Sparkes et al 1991]). Titers appear to rise progressively in many cats as they go from a subclinical to clinical stage of disease ([Pedersen et al 1987a]). However, progressive monitoring of titers is rarely done and titers are usually measured when disease signs appear and titers levels have already plateaued. Moreover, titers may also fall dramatically at the end, especially in cats with fulminating effusive FIP.

The sensitivity and specificity of so-called FIP serology has been repeatedly questioned. Hematology, antibody titers and serum protein electrophoresis from 48 cats (34 effusive and 14 noneffusive forms) affected with feline infectious peritonitis (FIP) were studied and compared with those of 20 healthy cats ([Sparkes et al 1991]). In the effusive form, antibody titers and protein electrophoresis in the effusions were analyzed. Seropositive animals (antibody titer $> 1:100$) were present among both the FIP infected (73%) and healthy cats (70%). [Sparkes et al (1991)] also compared serologic data from 65 cats in which FIP was considered as a differential diagnosis, but ended up having another disease. They found that the presence of multiple abnormalities compatible with FIP increased the specificity (i.e., decreased false positives), but decreased the sensitivity of the diagnosis (i.e., increased false negatives). However, there is no doubt that cats with very low or negative ($\leq 1:25$) feline coronavirus antibody titers are less likely to have FIP, while cats with very high titers ($\geq 1:1600$) are more likely. Given these limitations, this author recommends that FIP serologic tests only be used as an aid in ruling in or out the possibility of FIP. The diagnosis of FIP should never be made on antibody titers alone, a recommendation made by others ([Bell et al 2006b] and [Hartmann et al 2003]).

There have been many attempts to improve the specificity and sensitivity of antibody based tests for FIP. One commercial test measures antibody titers to the 7b protein of feline coronavirus based on the presumption that prototypic FECV (WSU-79-1683) lacks a 7b protein, while the prototypic FIPV (WSU-79-1146) has an intact 7b protein. In theory, cats with FIP should have antibodies to the 7b protein, while cats exposed to the common FECV would not have such antibodies. Unfortunately, the lack of 7b protein in WSU-79-1683 is an artifact of that specific isolate and field strains of FECV have an intact 7b gene ([Herrewegh et al 1995]). Therefore, the 7b antibody test is no more specific or sensitive than the indirect IFA test and this has been substantiated by published studies ([Bell et al 2006b; Kennedy et al 2008]).

Because of the vagaries of FIP serology, FIP antibody testing should also not be used as a means to control or eliminate FIP from catteries. Vast amounts of money are spent each year by cattery owners on FIP testing. In almost all cases, the results are non-interpretable, even by the veterinarians ordering the testing. Virtually all catteries having 6 to 8 cats and an active breeding program will have FECV in their cattery and 50-80% or more of their animals will have titers of 1:100 or greater (usually 1:25-1:1600). Cattery testing usually confirms what is already known, that FECV is enzootic in the cattery. Antibody titers do not answer the critical questions: 1) do any of the cat actually have FIP?, 2) are any of the cats subclinically infected with FIPV, 3) will a particular cat develop FIP in the future?, and 4) which cats are shedding FECV? Over- and mis-interpretation of various coronavirus antibody tests result in considerable mortality from senseless euthanasia of healthy cats and undue emotional and financial stress.

Serology has also been applied to the diagnosis of the neurologic form of FIP. [Foley et al \(1998\)](#) observed what they believed to be specific feline coronavirus antibody production within the CNS. They found that the most useful antemortem indicators of neurologic FIP were positive IgG anti-coronavirus antibody titer in the cerebral spinal fluid (CSF), high serum total protein concentration, and MRI findings suggesting periventricular contrast enhancement, ventricular dilatation and hydrocephalus. The diagnostic value of positive anti-coronavirus antibody titers in CSF was later questioned by [Boettcher et al \(2007\)](#). They collected CSF from four clinical groups: 1) cats with FIP involving the CNS (n = 10); 2) cats with FIP not involving the CNS (n=13); 3) cats with CNS disorders caused by diseases other than FIP (n=29); and 4) cats with diseases other than FIP and not involving the CNS (n=15). Cerebrospinal fluid was evaluated for concentrations of erythrocytes, leukocytes, and total protein. Anti-coronavirus IgG was measured in CSF and serum by indirect immunofluorescence assay. CSF IgG (1:32 to 1:4,096) was detected in 12 cats, including 6 cats with neurologic manifestation of FIP, 4 cats with FIP not involving the CNS, and 2 cats with brain tumors. CSF IgG was detected only in cats with correspondingly high serum IgG titers (1:4,096 -1:16,384) and significantly correlated with serum IgG titers. In another attempt to measure local CNS antibody production in cats with FIP, [Steinberg et al \(2008\)](#) used an albumin quotient and IgG index to determine whether proteins in the cerebrospinal fluid were of blood or local origin. Neither the albumin quotient nor IgG index identified a pattern consistent with intrathecal IgG synthesis in cats with the CNS form of FIP. The conclusion of these various studies is that coronavirus antibodies will enter the CSF when they are at very high levels in the serum; high serum titers are likely to be associated the dry form of FIP ([Pedersen, 1976a](#)), most neurologic cases of FIP are of the dry type (Table 2); therefore, positive feline coronavirus antibody titers in the CSF are likely to be associated with FIP.

Tests for the presence of FIPV RNA have been developed, but suffer from many of the same weaknesses as serology. Some of the more popular PCR based tests are based on the lack of the 7b gene in the FECV prototype WSU-79-1683 and its presence in the FIPV prototype WSU-79-1146. As mentioned above, the lack of the 7b gene in this one isolate is an artifact, probably of tissue culture adaptation. Therefore, PCR tests based on genetic differences between WSU-79-1146 and WSU-79-1683 are invalid. Moreover, PCR tests are notoriously susceptible to laboratory contamination with the DNA products of amplification. Many commercial laboratories do these procedures in an uncontrolled manner. In an attempt to increase specificity and sensitivity, a PCR was developed that would only detect forms of the viral RNA that were present during its replication stage (Simons et al 2004). The rationale was that replicating forms of the viral RNA would only be found in the blood of cats with FIP. The test was designed to amplify subgenomic mRNA of the highly conserved M gene. The test was applied to 424 healthy and 651 cats suspected of having FIP. Almost one-half of the diseased cats were positive for the replicating form of feline coronavirus mRNA in their peripheral blood cells, whereas only 5% of healthy cats tested positive. Seventy five of 81 cats (93%) with post-mortem confirmed FIP tested positive, whereas 17 non-FIP cases all tested negative. Such optimistic results were not found when the same test was applied to another group of cats. In this study, 26 blood samples were collected from 25 healthy cats and one cat with clinical signs suggestive of feline infectious peritonitis (FIP), namely, fever, weight loss, enlarged abdomen, and ascites (Can-Sahna et al 2007). Blood samples were then tested for replicating feline coronavirus messenger RNA by the procedure of Simons et al (2004). Fourteen (54%) of the cats were positive for FCoV including the cat with clinical disease, but a high rate of positivity was also observed among healthy cats, suggesting that feline coronaviruses may be present in the blood samples from healthy cats as well as cats with clinical FIP. This suggestion has been confirmed for healthy cats by others ([Kiss et al 2000] and [Meli et al 2004]). These conflicting findings call into question the value of PCR for testing of blood. However, RT-PCR has accurately differentiated FIP effusions from effusions of other causes (Hartmann et al 2003). The problem of laboratory contamination with PCR products can be virtually eliminated by using a technique called real time PCR (TaqMan).

Some clinicians and cattery owners will test for feline coronavirus in feces by PCR in an attempt to identify FECV carriers within groups of cats and eliminate shedders from the environment as a means to prevent FIP losses. FECV is shed at high levels in the feces, but the carrier rate is 40-80% or higher in many multi-cat populations and shedding is intermittent and infections recurrent (reviewed by Pedersen et al. 2008). PCR inhibitors have been described in feces, so it is important to purify viral RNA using certain methods (Dye et al. 2008). Such testing is expensive, and only a few laboratories can do it reliably on a commercial basis. However, in the final analysis, it is virtually impossible to maintain a group

of cats free of the virus, even if the infection can be eliminated, without strict quarantine facilities and measures, as well restricting the movement of cats and people between cat populations (see treatment and prevention).

Rivalta's test has touted for the diagnosis of wet FIP ([Hartmann et al 2003](#)). A test tube is filled with distilled water and one drop of 98% acetic acid is added, followed by a drop of the peritoneal or pleural effusion. If the drop dissipates in the solution, the test is negative, and if the drop retains its shape, the test is positive. A negative Rivalta's test is reportedly 97% accurate in ruling out FIP, while a positive test is 86% accurate in ruling in FIP. This author sees no improvement in diagnostic value of this test over routine gross, microscopic, and biochemical analysis of the fluid, but it is a simple and cheap supportive test.

Several indirect tests, usually based on the levels of certain inflammatory proteins or byproducts (acute phase reactants), have been used to detect inflammatory conditions in cats, and in particular FIP ([reviewed by Paltrinieri 2008](#)). Alpha-1-acid glycoprotein (AGP) is an acute phase protein that increases in concentration in infectious and inflammatory conditions. The serum and peritoneal fluid concentrations of AGP has been found useful in the diagnosis of feline infectious peritonitis (FIP) ([Bence et al 2005](#)) and ([Saverio et al 2007](#)). AGP and amyloid A both increase a few hours after the inflammatory stimulus and remain elevated for as long as the inflammation persists and have been evaluated in cats. Serum AGP levels have also been used to study FIP in groups of cats ([Paltrinieri et al 2007](#)). Serum AGP concentrations were observed to fluctuate over time in clinically healthy cats from catteries with the highest prevalence of feline infectious peritonitis (FIP) and significantly increased just before an outbreak of FIP. Although increased levels of AGP and other inflammatory proteins are particularly common in cats with FIP ([Saverio et al 2007](#)), they are not specific. Levels of AGP are usually high in cats with FIP and other inflammatory diseases; moderate serum AGP levels (1.5-2 mg/ml) can discriminate cats with FIP from other diseases that have a low pretest probability, while high serum AGP levels (>1.5- 3 mg/ml) are not usually seen in cats with diseases other than FIP ([Duthie et al 1997](#)) and ([Saverio et al 2007](#)). However, the specificity of increased AGP levels has been questioned by others ([Duthie et al 1997](#)). The potential value of raised levels of the acute phase reactants, alpha 1-acid glycoprotein (AGP) and haptoglobin in the diagnosis of FIP was examined in cats with confirmed FIP and in cats with other conditions. Levels of AGP greater than 1.5 g/litre in serum, plasma or effusion samples were found to be of value in distinguishing field cases of FIP from cats with similar clinical signs and differentiated these two groups of cats more effectively than the albumin: globulin ratio. The concentration of haptoglobin was higher in cats with FIP than in the group of healthy cats, but not sufficiently to be of diagnostic value. Serum samples from feline immunodeficiency virus-infected cats also had significantly elevated levels of AGP and haptoglobin, illustrating that raised levels of

these inflammatory proteins are not pathognomonic for FIP. Modifications of AGP have also been tested to increase its specificity ([Ceciliani et al 2004](#)). AGP in humans is heavily glycosylated and undergoes several modifications of its glycan moiety during acute and chronic inflammatory processes. Using human test modifications, feline AGP had very little L-fucose residues on its surface and its branching degree was very low in normal and in several pathological conditions. In contrast, feline AGP underwent several modifications during acute FIP, including decreased expression of both alpha (2-6)-linked and alpha (2-3)-linked sialic acid (76 and 44%, respectively) when compared to non-pathological feline AGP. The possible role of some acute phase (inflammatory) proteins and immunoglobulins in both the pathogenesis and diagnosis of feline infectious peritonitis (FIP) was also reported by [Giordano et al \(2004\)](#). Serum protein electrophoresis and the concentration of haptoglobin (Hp), serum amyloid A (SAA), alpha(1)-acid glycoprotein (AGP), IgG and IgM were evaluated in healthy coronavirus exposed cats and cats with FIP. The highest concentration of acute phase proteins was detected in affected cats, confirming the role of these proteins in supporting a clinical diagnosis of FIP. Interestingly, healthy coronavirus exposed cats also had increased acute phase proteins at the same time that members of the group developed FIP appeared in the group. However, this increase persisted only in cats that developed FIP. It is apparent from these various studies that levels of AGP, as well as other inflammatory proteins, change dramatically in FIP, but that none of these changes are definitive in their own right.

Magnetic resonance imaging (MRI) has proven useful in confirming the presence of inflammatory neurologic disease indicated by CSF analysis ([Negrin et al 2007](#)). Fourteen cats with inflammatory diseases affecting the CNS were reviewed, including eight cats with FIP and two cats with toxoplasmosis. Abnormalities affecting the CNS were observed in MR images in 10/14 (71%) cats. Intracranial lesions appeared as slightly hypointense foci in T1-weighted images in two (14%) cats, as hyperintense foci in T2-weighted images in seven (50%) cats, and as hyperintense foci after intravenous administration of a gadolinium-based contrast medium in 10 (71%) cats. In six cats with lesions in T1- and/or T2-weighted images, additional lesions were visible in T1-weighted images obtained after gadolinium-based contrast medium administration. In three cats, lesions were visible only after contrast medium administration. MRI in this study did not detect all cases of CNS inflammation in a population of cats with inflammatory cerebrospinal fluid (CSF). However, it did add important information on the location of lesions, which can be important in differentiating FIP from other inflammatory conditions. This substantiated the conclusions of an earlier MRI study on cats with neurologic FIP ([Foley et al 1998](#)). Sixteen domestic cats with confirmed neurologic FIP and 8 control cats with non-neurologic FIP were studied pre- and ante-mortem. MRI imaging demonstrated periventricular contrast enhancement, ventricular dilatation, and hydrocephalus in cats with neurologic FIP.

The present gold standard for FIP diagnosis is immunohistochemistry on effusions or lesions containing infected macrophages. Monoclonal or polyclonal antibodies that are highly feline coronavirus specific, and that will react well with formalin fixed tissues, have been used ([Tammer et al 1995](#)). Sections of lesions or cell pellets from ascetic or pleural fluids can be directly examined for virus using fluorescein or horse radish peroxidase polyclonal or monoclonal antibodies. Detection of coronavirus antigen in FIP effusions is very specific, but less sensitive than detection of viral antigens in characteristic FIP parenchymal lesions. [Hirschberger et al \(1995\)](#) identified antigen in 34/49 confirmed FIP effusions, whereas 50 effusions due to other causes were negative. The specificity of immunohistochemistry is a factor of the poly- or mono-clonal antibodies used and the characteristic localization of FIPV antigen within macrophages ([Paltrinieri et al 1998](#)) and ([Tammer et al 1997](#)). The sensitivity of the test depends on having infected macrophages in the tissues or exudate cells on the slides. For this reason, random biopsy of liver or kidney of cats with FIP often fail to yield FIPV antigen by immunohistochemistry ([Giordano et al 2005](#)), and the same would be true for real time PCR. Sensitivity is 5-10 times greater with fluorescein than horse radish peroxidase staining, but the latter has the advantage of using formalin fixed and paraffin embedded tissues, while the former requires frozen sections of tissues. Both can be used with equal ease on slides of cells harvested from effusions and acetone fixed.

Virus isolation in tissue culture has not been yet possible for FECVs and is difficult for most field strains of FIPV. Serotype II FIPVs seem to grow better in tissue culture, and will often grow on both Crandell feline kidney (Crfk) and *Felis catus* whole fetus-4 (Fcwf-4 cells). The latter cell line is of macrophage lineage [Jacobse-Geels and Horzinek \(1983\)](#) and is the preferred cell line for the isolation of serotype I FIPVs ([Pedersen et al 1981a](#)) and ([Pedersen and Floyd 1985](#)). The cost and low yield of cell culture isolation prohibits its routine application to clinical diagnosis.

Following introduction of tests for detection of FeLV infection, one third or more of cats with FIP were found to have concomitant FeLV infections ([Cotter et al 1973, 1975](#)). With elimination of FeLV from many catteries and pet cat households, and the steady decline in the incidence of FeLV in the entire cat population, the proportion of cats with FIP and concurrent FeLV infections has greatly decreased. At the present, virtually all cases of FIP in purebred cattery-bred cats are FeLV negative, and FeLV infection is detected in 10% or less of domestic pet cats with FIP.

Treatment and Prevention

It must be stated at the onset that no treatment has proven effective in curing cats of FIP, in spite of the claims. Cats that develop FIP inevitably die of their disease in days, weeks or months. The reason for these numerous false claims is uncertain, but spontaneous remissions may account for at least some reports and misdiagnosis for the remainder. Cats with ocular signs and no other systemic manifestations of FIP have occasionally gone into remission with just symptomatic treatment. Cats with chronic fever, enlarged mesenteric lymph nodes that were histologically compatible with FIP, and high coronavirus titers, have gone into remission without treatment. Some cats without overt signs of FIP have demonstrated fibrous lesions on the spleen and liver when necropsied for other reasons, indicating a previous bout of FIP. Small quiescent lesions in the spleen and mesenteric lymph nodes have also been found in otherwise healthy cats upon routine ovariohysterectomies. Therefore, spontaneous remissions occur and at least some of these natural responses may have fortuitously coincided with various treatments. Cures were first reported with tylosin and prednisolone (Colgrove and Parker 1971), sparking a decade of tylosin use for treatment of FIP. However, tylosin has no effect on FIP. Interestingly, a significant proportion of cats with FIP are still treated with an antibiotic of one type or the other. Some cats have gone into remission after use of prednisolone and phenylalanine mustard or cyclophosphamide (Pedersen 1976a). Another cat was successfully “treated” with prednisolone and phenylalanine mustard (Madewell et al 1978). No immunosuppressive drug regimen has withstood the test of time.

A number of other equally dubious non-specific treatments have been used for FIP, almost all with insufficient patient numbers, inadequate documentation of infection, or lack of essential placebo controls and double blinding (Hartmann and Ritz 2008). FIPV is very sensitive to human alpha and beta interferons *in vitro* (Weiss and Toivio-Kinnucan 1988). Feline interferon omega also will inhibit FIPV *in vitro* and is commercially available in many countries (Mochizuki et al 1994). Feline interferon omega reportedly induced complete or partial remissions in two thirds of cats with FIP (Ishida et al 2004). However, in a larger and double blinded study, this treatment was found to be totally ineffective (Ritz et al 2007). Various immunosuppressants such as glucocorticoids and cyclophosphamide have been used, but these drugs may prolong life but do not alter the fatal outcome (Hartmann and Ritz 2008). Immunostimulants, megadoses of vitamins, and numerous nutraceuticals have also been advocated but found to be without merit. Pentoxifylline, a tumor necrosis factor alpha inhibitor (Zabel et al 1993), has been used on cats with FIP based on its benefit in treating some types of human and feline vasculitis (Nichols et al 2001). TNF-alpha is upregulated in FIP (Kiss et al 2004) and FIP is basically a vasculitis. However, this treatment has not proven

beneficial on its own and has fallen from use. We have treated one FIP cat with feline IFN- γ and a TNF- α inhibitor (pentoxifylline) with no beneficial affect.

Effective vaccines have been as elusive as effective treatments. [Pedersen \(1989\)](#) hypothesized that the ideal FIPV vaccine should contain a live virus that would persist in the body in a subclinical state, inducing a state of premonition immunity. However, a successful vaccine against FIP has not been developed, even though most have been based on this hypothesis. Cats that survive infection with a progressively increasing dose of virus, starting with sub-lethal levels, appear to develop a type of immunity ([Pedersen and Black 1983](#)). However, this approach is not clinically applicable, because as many cats die as become immune, and immunity appears to be tenuous. Some cats that appear to have resisted disease have developed FIP months or years later, indicating the persistence of subclinical infections. This finding was supported by a subsequent study by [Baldwin and Scott \(1997\)](#). They first immunized cats intratracheally with a sublethal dose of virulent FIPV, followed by a high dose of temperature attenuated virus. Cats demonstrated immunity to an aerosol challenge with highly virulent FIPV but residual lesions were found upon necropsy examination suggesting that immunity was either partial or of the premonition type. Early attempts to use an attenuated live FIPV strain, FIPV-Black_{high passage}, to induce immunity failed to provide protection and even caused immune enhancement. A similar finding was reported later for a virulence attenuated strain of FIPV-UCD1 ([Kiss et al 2004](#)). The phenomenon of FIPV vaccine induced enhancement has been recently reviewed and is a common theme in many vaccine approaches ([Huisman et al 2008](#)).

A temperature sensitive mutant of FIPV-79-1146, administered intranasally, was later developed and corporate studies showed a high degree of efficacy against challenge with highly virulent FIPV-79-1146 ([\[Christianson et al 1989\]](#) and [\[Gerber et al 1990\]](#)). Immunity was ascribed to a local IgA response and systemic cellular response measured by FIPV induced lymphocyte proliferation. This vaccine is given as two intranasal doses, three or more weeks apart, starting at 16 weeks or older. Presumably, efficacy could not be shown for cats vaccinated and/or challenge-exposed at a younger age. This commercial vaccine was studied in the field in a large single building shelter housing a thousand or more cats ([\[Postorino-Reeves et al 1992\]](#) and [\[Reeves et al 1992\]](#)). Five hundred FIV/FelV negative, feline coronavirus antibody negative cats were divided into two groups prior to being put into this environment. One half got the intranasal live vaccine and one half was sham vaccinated. The cats were then followed for 16 months. Overall deaths in both groups were the same. However, two cats in the vaccinated group developed FIP during the 16 months and 8 non-vaccinated cats succumbed to the disease. Protection in this study was not convincing and the validity of using the vaccine only on coronavirus negative cats and measuring protection over a limited period of time were questioned ([Wolf 1997](#)). [Hoskins et al \(1994\)](#) vaccinated

20 SPF cats intranasally at 16 and 19 weeks of age, and added 20 non-vaccinated controls. All 40 cats were then challenge-exposed orally at 23 weeks of age with FIPV-DF2 (i.e., FIPV-79-1146). One vaccinated and 5 non-vaccinated cats developed effusive FIP and were euthanized. However, 6 of the remaining vaccinates and 12 of the remaining controls had histologic evidence of FIP when necropsied 8 weeks later. [Wolf \(1997\)](#) criticized this study for using a homologous challenge strain and for only following the cats out 8 weeks. In a second field study, the vaccine failed to prevent FIP in cattery kittens immunized in the presence of pre-existing FECV antibodies ([Fehr et al 1997](#)). The issues of serotype specificity (i.e., the vaccine is against serotype II, while most field isolates are serotype I), interference with maternal antibodies, the need to withhold vaccination until at least 16 weeks, and the relatively poor efficacy are serious limitations. This vaccine is still marketed, and is used by some veterinary practitioners. It has proven safe over a long period of use and does not appear to enhance disease ([Reeves et al 1992](#)). However, its degree of effectiveness in the general cat population, where the incidence of FIP is very low, and in catteries and multi-cat households where virtually all 16 week olds are already seropositive and therefore non-responsive, is highly questionable. Serotype cross-reactivity is also an issue. Cross protection between closely related viruses, such as TGEV or CCV, and FIPV either does not occur or is weak ([\[Stoddart CA et al 1988\]](#), [\[Woods 1984\]](#) and [\[Woods and Pedersen 1979\]](#)). Therefore, cross protection between serotypes is questionable; even between various isolates of the same serotype of FIPV can vary ([Pedersen 1987c](#)). Cats infected with FIPV-UCD2 neither become ill nor developed protective immunity against challenge exposure with more virulent strains. FIPV-UCD3 recovered cats tend to be immune to challenge with FIPV-UCD1, while FIPV-UCD4 recovered cats do not have good protective immunity to FIPV-UCD1.

There have been a number of different potential vaccines based on recombinant technology described in the literature since 1990. A genetically engineered vaccinia virus expressing the envelope protein of FIPV has been tested ([Vennema et al 1990](#)); it enhanced virulent FIPV infection rather than protecting cats. [Wasmoen et al \(1995\)](#) developed a recombinant raccoon poxvirus that expressed the gene encoding the nucleocapsid protein of FIPV and used it as a vaccine. Cats were parenterally or orally vaccinated twice, three weeks apart, and then infected orally with FECV to sensitize them to virulent FIPV. Three weeks later, cats were orally challenged with FIPV; 4/5 (80%) nonvaccinated controls succumbed to FIP, while 0/5 cats vaccinated subcutaneously with the raccoon recombinant pox virus developed FIP. One of the five cats in this latter group died following a second FIPV challenge, suggesting immunity was of the premonition type. Vaccination induced serum antibody responses to FIPV nucleocapsid protein, but they were not neutralizing. This suggested that the protective immune response involved a mechanism other than neutralizing antibodies to the Spike glycoprotein or that FECV boosting was important for immunity. The subsequent

fate of this vaccine approach is unknown. In another study, the spike gene of FECV-79-1683 was cloned into vaccinia virus and used as an expression vector vaccine (Klepfer et al 1995). Vaccinated cats developed neutralizing antibodies, but kittens vaccinated with the recombinant vaccinia virus died earlier than animals vaccinated with native vaccinia virus alone. A plasmid vaccine containing the membrane (M) and nucleocapsid (N) genes failed to protect kittens against a challenge infection with FIPV (Glansbeek et al 2002), while a vaccinia virus expressing the M protein of FIPV failed to protect cats against FIPV-79-1146 (Hebben et al 2004). A vaccine made up of a cell lysate of recombinant baculovirus-expressed FIPV-KU-2 nucleocapsid protein protected 6/8 vaccinates vs. 1/8 of cats immunized with a control antigen (Hohdatsu et al 2003). Haijema et al (2004) reported successful vaccination of cats against a homologous virus challenge of cats with a live FIPV that has been attenuated by deletion of the 3a-c, and to lesser extent 7ab gene clusters. No follow up research has been reported on these latter two vaccine approaches.

Antiviral drug therapy has become increasingly important in a number of viral diseases such as HIV and human influenza virus. Ribavirin, which is strongly inhibitory of FIPV *in vitro* (Barlough and Scott 1990), is not effective *in vivo* (Weiss et al 1993). This dichotomy between *in vitro* and *in vivo* inhibition is mirrored by recent experience with the human SARS coronavirus (Barnard et al 2006). Sixteen different compounds were subsequently tested for their ability to inhibit feline coronavirus replication *in vitro*; six of the compounds were found to reduce the virus titers by 0.401 to 0.833 log₁₀ (P < 0.05), using cytopathic effect as the endpoint (Barlough and Shacklett 1994). The 50 per cent effective dose (ED₅₀) levels for these six compounds was pyrazofuin > 6-azauridine > 3-deazaguanosine > hygromycin B > fusidic acid > dipyrindamole, respectively. Compounds that had no statistically significant effect on FIPV in the same assay were caffeic acid, carbodine, 3-deazauridine, 5-fluoroorotic acid, 5-fluorouracil, D(+)-glucosamine, indomethacin, D-penicillamine, rhodamine and taurine. No subsequent *in vivo* studies were reported on the compounds that were inhibitory *in vitro*. The more recent appearance of severe acute respiratory syndrome (SARS) in humans has greatly increased interest and knowledge of other potential anti-coronaviral drugs. A wide variety of pyridine N-oxide derivatives have been found to be inhibitory against feline coronavirus (FIPV strain) and human SARS-CoV (Frankfurt strain-1) in CRFK and simian kidney (Vero) cell cultures, respectively (Balzarini et al 2006a). The most selective compounds were active at a high microgram per liter range and non-toxic at 50-100 mg/L. One of the most active and selective compounds tested was shown to inhibit feline coronavirus replication at the transcriptional level. Balzarini et al (2006b) also demonstrated inhibition of FIP and human SARS coronaviruses by semisynthetic derivatives of glycopeptide antibiotics including vancomycin, eremomycin, teicoplanin, ristocetin A and DA-40926. The 50% effective concentrations (EC₅₀) for the most active derivatives were in the lower micromolar range. The EC₅₀ values differed between FIPV and SARS-CoV, indicating

considerable differences in species specificity. No *in vivo* studies on any of these feline coronavirus inhibitory compounds have been reported to date. Indomethacin has recently been found to have a potent inhibitory effect on replication of both SARS coronavirus and CCV, but no studies were done on feline coronaviruses by this group (Amici et al 2006). However, an earlier study found indomethacin to be ineffective against FIPV (Barlough and Shacklett 1994).

The incidence of FIP within catteries can be decreased by proper management (Pedersen et al., 1995). Mortality tends to increase as the population of animals, especially kittens, increases. The effect of overcrowding on FIP incidence has been particularly evident in animal shelters. FIP losses inevitably increase when shelters are overwhelmed with cats, usually during kitten season, and decrease when overcrowding is controlled; longer shelter stays compound the situation (K. Hurley, UC Davis, unpublished information, 2008). Losses from FIP are also proportional to the severity of other kittenhood diseases, including those caused by herpesvirus, calicivirus, chlamydia, mycoplasma, dermatophytes, and numerous other bacterial, viral, fungal, protozoal, and parasitic skin, upper respiratory and enteric infections. Kittens kept in crowded catteries or shelters with a large number of other young animals suffer greatly from concurrent diseases. These diseases stress the kittens' immune system and cause a decrease in growth rate and an increase in susceptibility to disease in general. Feline leukemia virus infection, a bane of many catteries, shelters and other multi-cat environments in the past, was once the single most powerful potentiator of FIP in cats. Fortunately, FeLV infection has been pushed back into nature in most westernized countries by an aggressive campaign of testing, eradication/isolation of shedders and vaccination, and is no longer a problem in most multi-cat environments (Weijer et al 1989). Genetics also play an important role in FIP. Genetic resistance/susceptibility factors also affect FIP incidence and obviously have their strongest influence in catteries. Death losses from FIP can sometimes be traced to certain breedings, and further breeding of pairs that produced affected kittens should be avoided. Toms that produce litters that suffer from FIP should be especially avoided, because a given male affects far more litters and individuals than a queen (Foley and Pedersen 1996). Breeding practices in catteries often result in an abundance of younger breeding animals. The incidence of FIP in a static multi-cat household is known to decrease over 3 years (Addie et al 1995). This may be associated with age resistance to chronic or intermittent FECV shedding; an immunity of sorts develops over a period of many months or years (Pedersen et al 2008). Age resistance over this period of time is seen with several chronic type infections, such as herpesvirus, FCV, FeLV and ringworm. This is why catteries or shelters that keep mainly older cats have much less infectious disease problems than catteries with younger breeding or sheltered animals.

The practice of isolating queens and early weaning of kittens has been advocated for the control of FIP in catteries ([Addie et al 2004](#); [Addie and Jarrett 1995](#)) and is widely practiced. Cattery kittens are not infected with FECV until around 9-10 weeks of age ([Pedersen et al 2008](#)). If queens are isolated just prior to parturition, kept in strict quarantine from other sources of FECV exposure, removed from their kittens at the earliest possible time (4-6 weeks after birth), and kittens maintained thereafter in isolation, it is possible to prevent kittens from becoming infected with FECV and hence prevent FIP. However, this practice works best on small catteries, and in larger catteries or breeding colonies it requires very elaborate quarantine facilities and strict control of exposure ([Hickman et al 199?](#)). Gross and microscopic litter dust contains high levels of virus. Such litter dust is omnipresent and easily spread through the air, caging, pans, accessories and on clothing. Therefore, strict quarantine involves separate quarters and caregivers, separate litter, food and water pans, separate air space, and change-in/change-out protective clothing including shoes/shoe covers/boots, foot baths, etc. Isolation facilities cannot consist of just another room in a home, with no other special precautions. If specifically designed isolation rooms are not available, an alternative would be to transfer kittens at early weaning to distant facilities (or homes) devoid of other cats. The problems with the “isolation of pregnant queens and early weaning program” are several folds. First, the level of quarantine required to prevent contamination requires expensive facilities and great costs to operate them. Second, what should be done with coronavirus free kittens once they are produced? Infection with coronavirus is almost assured once these kittens are reintroduced into the normal environment and expected to carry out normal activities, such as relocation to new homes, showing and breeding. However, there remains one advantage of a successful isolation and early weaning program, and that is to delay infection until after the kittens are 16 weeks of age or older. This is a time when the immune system begins to attain adult levels of activity and when kittens become more resistant to clinical disease of all sorts, including FIP.

Catteries that undertake isolation and early weaning programs should determine whether it is working given their facilities and level of husbandry. If kittens coming out an early weaning program are found to be seropositive at 16 weeks of age and/or shedding FECV from their feces, the program has failed. Given costs and logistical problems, this author does not highly recommend isolation and early weaning programs, especially for larger catteries (over 6 breeding cats). The most cost-effective means to control FIP losses are five-fold: 1) eliminate over-crowding, and if possible, maintain no more than 6 breeding animals; 2) maintain a larger proportion of older cats (3 years of age and older); 3) manage feces to mouth spread by properly managing litter boxes, litter replacement, and gross and microscopic spread of litter and litter dust; 4) be highly selective in the breeding program and produce a minimum number of litters, and 5) control genetics by not using any tom (at a minimum) that has produced kittens that have developed FIP, or preferably, use neither toms

nor queens that have produced kittens that died from FIP. These steps are far more effective than improperly conducted isolation and early weaning programs and can be easily implemented.

Natural immunity

Natural immunity to the mutant form of FECV (i.e., FIPV) does exist based on experimental studies. Virtually every study that involves experimental FIPV infection, whether it concerns a vaccine or some aspect of pathogenesis, has cats that survive very high exposures to highly virulent virus. Since husbandry factors are largely standardized in such studies, resistance or susceptibility can be narrowed to one factor – the ability of the individual cat to institute a strong and durable immune response to the FIPV. Natural immunity is not nearly so evident when dealing with field cases of FIP, because virtually all cats that become clinically ill with the disease will die over a period of days, weeks, months and sometimes years.

Observations with the naturally occurring disease paint a much more pessimistic picture. However, it must be realized that the cats that develop FIP in the field and in our homes are the ones that have failed to mount an effective and durable immune response. They have already lost their personal battle, just as the portion of cats that die following experimental infection. What then, are the factors that will tip the balance of the immune response to FIPV in favor of the host?

Both genetic ([Foley and Pedersen 1996](#)) and host ([Poland et al 1996](#)) factors appear to have a strong influence on resistance of susceptibility to FIPV in nature.

Genetic resistance factors are undoubtedly involve more than one gene and probably involve numerous genes working in some sort of concert. Based on genetic studies of human resistance to infections and to autoimmunity, most resistance genes will be involved with various aspects of immune recognition and regulation. Although many genes may be ultimately linked to resistance/susceptibility, there will be probably a handful of genes that play major roles and will serve as a basis for genetic selection for resistance.

Environmental factors would seem to account for one half of the FIP disease incidence. However, the identity of these factors is uncertain. FIP losses are definitely higher among cats that spend their early kittenhood in large multiple cat households such as catteries, shelters, and foster shelters. Overcrowding and intermingling of kittens, adolescent and older cats are a common feature of such environments and are obvious contributors to other infections of cats. The age at which a kitten is exposed to FECVs is probably also crucial. Most kittens will show no signs of FECV shedding before 9 weeks of age, indicating that they can become infected a week earlier (to allow for an incubation period). We know that the FIPV mutation occurs in up to 20% of cats undergoing primary FECV infection ([Poland et al 1996](#)), but that only a portion of these kittens will go on to develop FIP. Age is probably one

of the most important risk factors other than FECV exposure and genetic susceptibility. We know that older cats exposed to FECV, and with normal immune systems, will not get sick. In contrast, one in five older cats exposed to FECV at the same time and manner, and with compromised immune systems, will develop FIP. We also know that young kittens will shed 10 to 100 times more FECV following primary infection than older cats. The higher the level of virus replication in the gut, the greater the likelihood that a mutation will occur. Finally, we know that kittens in the 8-12 week age range are just starting to become immunocompetent and that near adult levels of immunity are not achieved until 16 weeks and later. Therefore, most cattery and shelter kittens are exposed to FECV, and therefore to its mutants, at an age when they are not fully immunocompetent. If this infection were to be delayed for several more weeks or months, the likelihood of the FIPV mutant taking hold would undoubtedly be greatly decreased.

FeLV is a potent potentiator of FIP. Thirty five cases of FIP were observed among 500 conventional (non-SPF except for FeLV) cats that had been experimentally infected with FeLV by natural contact or experimental infection ([Pedersen et al 1977] and [Pedersen 1987a]). FIP deaths occurred within a relatively short time after they became FeLV viremic, and only one cat in a similar cohort of non-FeLV exposed cats died of FIP. Antibody titers to FIPV began to raise progressively after the cats became viremic for FeLV and reached high levels prior to death from FIP (Pedersen 1987a).

Animal and Public Health Considerations

Feline infectious peritonitis virus is a naturally occurring infection of domestic and wild Felidae. People are not hosts for the virus. Dogs and swine can be experimentally infected with FIPV. One of the first commercial canine coronavirus vaccines for dogs may have actually consisted of FIPV; hundreds of dogs died of severe neurologic and pancreatic disease before it was recalled (Martin, 1985). However, the fact that very few if any cats with FIP shed FIPV not only limits its transmission from cat-to-cat, but from cat-to-dog. Therefore, we do not see FIPV infections of dogs in nature. A mild to moderately severe TGE-like syndrome occurs in baby pigs (Woods et al 1981). However, it is doubtful that FIPV is a cause of naturally occurring disease in these species. Diseases closely resembling FIP of cats, and caused by species related coronaviruses, have been described in both ferrets ([Garner et al 2008], [Perpiñán and López 2008] and [Martinez et al 2008]) and mice ([France et al 1999] and [Kyuwa et al 1998a,b]).

References

Addie DD, Paltrinieri S, Pedersen NC (2008) Recommendations of the second international feline coronavirus/feline infectious peritonitis symposium. *Journal Feline Medicine and Surgery* 6, 125-30.

Addie DD, Jarrett O (2001) Use of a reverse-transcriptase polymerase chain reaction for monitoring the shedding of feline coronavirus by healthy cats. *Veterinary Record* 148, 649-53.

Addie DD, Toth S, Herrewegh AA, Jarrett O (1996) Feline coronavirus in the intestinal contents of cats with feline infectious peritonitis. *Veterinary Record* 139, 522-23.

Addie DD, Jarrett O (1995) Control of feline coronavirus in breeding catteries by serotesting, isolation, and early weaning. *Feline Practice* 23(3), 92-95.

Addie DD, Toth S, Murray GD, Jarrett O (1995) Risk of feline infectious peritonitis in cats naturally infected with feline coronavirus. *American Journal Veterinary Research* 56, 429-34.

Amici C, DiCoro A, Ciucci A, Chiappa L, Castilletti C, Martella V, Decaro N, Buonavoglia C, Capobianchi MR, Santoro MG (2006) Indomethacin has a potent antiviral activity against SARS coronavirus. *Antiviral Therapy* 11,1021-30.

Baldwin CW, Scott FW (1997) Attempted immunization of cats with feline infectious peritonitis virus propagated at reduced temperatures. *American Journal Veterinary Research* 58, 251-56.

Balzarini J, Keyaerts E, Vijgen L, Vandermeer F, Stevens M, DeClercq E, Egberink H, Van Ranst M (2006a) Pyridine N-oxide derivatives are inhibitory to the human SARS and feline infectious peritonitis coronavirus in cell culture. *Journal Antimicrobial Chemotherapy* 57, 472-81.

Balzarini J, Keyaerts E, Vijgen L, Egberink H, DeClercq E, VanRanst M, Printsevskaya SS, Olsufyeva EN, Solovieva SE, Preobrazhenskaya MN (2006b) Inhibition of feline (FIPV) and human (SARS) coronavirus by semisynthetic derivatives of glycopeptide antibiotics. *Antiviral Research* 72, 20-33.

- Barlough JE, et al (1982) The worldwide occurrence of feline infectious peritonitis. *Feline Practice* 12, 26-30.
- Barlough JE, Scott FW (1990) Effectiveness of three antiviral agents against FIP virus in vitro. *Veterinary Record* 126, 556-58.
- Barlough JE, Shacklett BL (1994) Antiviral studies of feline infectious peritonitis virus in vitro. *Veterinary Record* 135, 177-79.
- Barnard DL, Day CW, Bailey K, Heiner M, Montgomery R, Lauridsen L, Winslow S, Hoopes J, Li JK, Lee J, Carson DA, Cottam HB, Sidwell RW (2006) Enhancement of the infectivity of SARS-CoV in BALB/c mice by IMP dehydrogenase inhibitors, including ribavirin. *Antiviral Research* 71, 53-63.
- Bell ET, Toribio JA, White JD, Malik R, Norris JM (2006a) Seroprevalence study of feline coronavirus in owned and feral cats in Sydney, Australia. *Australian Veterinary Journal* 84, 74-81.
- Bell ET, Malik R, Norris JM (2006b) The Relationship between the feline coronavirus antibody titre and the age, breed, gender and health status of Australian cats. *Australian Veterinary Journal* 84, 2-7.
- Bence LM, Addie DD, Eckersall PD (2005) An immunoturbidimetric assay for rapid quantitative measurement of feline alpha-1-acid glycoprotein in serum and peritoneal fluid. *Veterinary Clinical Pathology* 34, 335-41.
- Boettcher IC, Steinberg T, Matiasek K, Greene CE, Hartmann K, Fischer A (2007) Use of anti-coronavirus antibody testing of cerebrospinal fluid for diagnosis of feline infectious peritonitis involving the central nervous system in cats. *Journal of American Veterinary Medical Association* 230, 199-205.
- Bradshaw JM, Pearson GR, Gruffydd-Jones TJ (2004) A retrospective study of 286 cases of neurological disorders of the cat. *Journal of Comparative Pathology* 131, 112-20.
- Campbell LH, Reed C (1975) Ocular signs associated with feline infectious peritonitis in two cats. *Feline Practice* 5, 32-35.
- Campbell LH, Schiessl MM (1978) Ocular manifestations of toxoplasmosis, infectious peritonitis and lymphosarcoma in cats. *Modern Veterinary Practice* 59, 761-64.

Cannon MJ, Silkstone MA, Kipar AM (2005) Cutaneous lesions associated with coronavirus-induced vasculitis in a cat with feline infectious peritonitis and concurrent feline immunodeficiency virus infection. *Journal Feline Medicine Surgery* 7, 233-36.

Can-Sahna K, Soydal Ataseven V, Pinar D, Oğuzoğlu TC (2007) The detection of feline coronaviruses in blood samples from cats by mRNA RT-PCR. *Journal Feline Medicine Surgery* 9, 369-72.

Cave TA, Thompson H, Reid SW, Hodgson DR, Addie DD (2002) Kitten mortality in the United Kingdom: a retrospective analysis of 274 histopathological examinations (1986 to 2000). *Veterinary Record* 151, 497-501.

Cecilian F, Grossi C, Giordano A, Pocacqua V, Paltrinieri S (2004) Decreased sialylation of the acute phase protein alpha1-acid glycoprotein in feline infectious peritonitis (FIP). *Veterinary Immunology Immunopathology* 99, 229-36.

Christianson KK, Ingersoll JD, Landon RM Pfeiffer NE, Gerber JD (1989) Characterization of a temperature-sensitive feline infectious peritonitis coronavirus. *Archives of Virology* 108, 185-96.

Colby ED, Low RJ (1970) Feline infectious peritonitis. *Veterinary Medicine Small Animal Clinic* 65, 783-86.

Colly LP (1973) Feline infectious peritonitis. *The Veterinary Clinics of North America* 3, 34.

Colgrove DJ, Parker AJ (1971) Feline infectious peritonitis. *Journal of Small Animal Practice* 12, 225-32.

Cotter SM, Gilmore CE, Rollins C (1973) Multiple cases of feline leukemia and feline infectious peritonitis in a household. *Journal of American Veterinary Medical Association* 162, 1054-58.

Cotter, SM, Hardy WD Jr, Essex M. (1975) The association of feline leukemia virus with lymphosarcoma and other disorders. *Journal of American Veterinary Medical Association* 168, 448-54.

- Declercq J, De Bosschere H, Schwarzkopf I, Declercq L (2008) Papular cutaneous lesions in a cat associated with feline infectious peritonitis. *Veterinary Dermatology* 19, 255-8.
- Foley, JE, Pedersen NC (1996) Inheritance of susceptibility of feline infectious peritonitis in purebred catteries. *Feline Practice* 24, 14-22.
- Foley JE, Lapointe JM, Koblik P, Poland A, Pedersen NC (1998) Diagnostic features of clinical neurologic feline infectious peritonitis. *Journal of Veterinary Internal Medicine*. 12, 415-23.
- Foley JE, Poland A, Carlson J, Pedersen NC (1997a) Risk factors for feline infectious peritonitis among cats in multiple-cat environments with endemic feline enteric coronavirus. *Journal of American Veterinary Medical Association* 210, 1313-18.
- Foley JE, Poland A, Carlson J, Pedersen NC (1997b) Patterns of feline coronavirus infection and fecal shedding from cats in multiple-cat environments. *Journal of American Veterinary Medical Association* 210, 1307-12.
- Fowler ME (1978) *Zoo and Wild Animal Medicine*. WB Saunders Co., Philadelphia, p 660.
- Foster RA, Caswell JL, Rinkardt N (1996) Chronic fibrinous and necrotic orchitis in a cat. *Canadian Veterinary Journal* 37, 681-82.
- France MP, Smith AL, Stevenson R, Barthold SW (1999) Granulomatous peritonitis and pleuritis in interferon-gamma gene knockout mice naturally infected with mouse hepatitis virus. *Australian Veterinary Journal* 77, 600-04
- Gelatt KM (1973) Iridocyclitis-panophthalmitis associated with feline infectious peritonitis. *Veterinary Medicine Small Animal Clinic* 68, 56-57.
- Gerber JD, Ingersoll JD, Gast AM, Christianson KK, Selzer NL, Landon RM, Pfeiffer NE, Sharpee RL, Beckenhauer WH (1990) Protection against feline infectious peritonitis by intranasal inoculation of a temperature-sensitive FIPV vaccine. *Vaccine*. 8, 536-42.
- Gillespie JH, Scott FW (1973) Feline viral infections. *Advances in Veterinary Science and Comparative Medicine* 17, 163-200.

Giordano A, Paltrinieri S, Bertazzolo W, Milesi E, Parodi M (2005) Sensitivity of Tru-cut and fine needle aspiration biopsies of liver and kidney for diagnosis of feline infectious peritonitis. *Veterinary Clinical Pathology* 34, 368-74.

Giordano A, Spagnolo V, Colombo A, Paltrinieri S (2004) Changes in some acute phase protein and immunoglobulin concentrations in cats affected by feline infectious peritonitis or exposed to feline coronavirus infection. *Veterinary Journal* 167, 38-44.

Glansbeek HL, Haagmans BL, te Lintelo EG, Egberink HF, Duquesne V, Aubert A, Horzinek MC, Rottier PJ (2002) Adverse effects of feline IL-12 during DNA vaccination against feline infectious peritonitis virus. *Journal of General Virology* 83, 1-10.

Goodhead AD (1996) Uveitis in dogs and cats: guidelines for the practitioner. *Journal of South African Veterinary Association* 67, 12-19.

Haelterman EO (1962) Epidemiological studies of transmissible gastroenteritis of swine. *US Livestock Sanitation Association Process* 66, 305-15.

Haijema BJ, Volders H, Rottier PJ (2004) Live, attenuated coronavirus vaccines through the directed deletion of group-specific genes provide protection against feline infectious peritonitis. *Journal of Virology* 78, 3863-71.

Hartmann K, Ritz S (2008) Treatment of cats with feline infectious peritonitis. *Veterinary Immunology Immunopathology*.123, 172-5.

Hartmann K, Binder C, Hirschberger J, Cole D, Reinacher M, Schroo S, Frost J, Egberink H, Lutz H, Hermanns W (2003) Comparison of different tests to diagnose feline infectious peritonitis. *Journal of Veterinary Internal Medicine* 17, 781-90.

Harvey CJ, Lopez JW, Hendrick MJ (1996) An uncommon intestinal manifestation of feline infectious peritonitis: 26 cases (1986-1993). *Journal of American Veterinary Medical Association* 15, 1117-20.

Harvey JW, Gaskin JM (1978) Feline haptoglobin. *American Journal of Veterinary Research* 39, 549-53.

Hayashi T, Utsumi F, Takahashi R, Fujiwara K (1980) Pathology of noneffusive-type feline infectious peritonitis and experimental transmission. *Japanese Journal of Veterinary Science* 42, 197-210.

- Hebben M, Duquesne V, Cronier J, Rossi B, Aubert A. (2004) Modified vaccinia virus Ankara as a vaccine against feline coronavirus: immunogenicity and efficacy. *Journal of Feline Medicine and Surgery* 6, 111-18.
- Herrewegh AA, Smeenk I, Horzinek MC, Rottier PJ, de Groot RJ (1998) Feline coronavirus type II strains 79-1683 and 79-1146 originate from a double recombination between feline coronavirus type I and canine coronavirus. *Journal of Virology* 72, 4508-14.
- Herrewegh AA, Mähler M, Hedrich HJ, Haagmans BL, Egberink HF, Horzinek MC, Rottier PJ, de Groot RJ (1997) Persistence and evolution of feline coronavirus in a closed cat-breeding colony. *Virology* 4, 349-63.
- Herrewegh AA, Vennema H, Horzinek MC, Rottier PJ, de Groot RJ (1995) The molecular genetics of feline coronaviruses: comparative sequence analysis of the ORF7a/7b transcription unit of different biotypes. *Virology*. 212, 622-31.
- Hickman MA, Morris JG, Rogers QR, Pedersen NC (1995) Elimination of feline coronavirus infection from a large experimental specific pathogen-free cat breeding colony by serologic testing and isolation. *Feline Practice* 23, 96-102.
- Hirschberger J, Hartmann K, Wilhelm N, Frost J, Lutz H, Kraft W. (1995) [Clinical symptoms and diagnosis of feline infectious peritonitis] *Tierärztliche Praxis* 23, 92-9.
- Hohdatsu T, Yamato H, Ohkawa T, Kaneko M, Motokawa K, Kusuhara H, Kaneshima T, Arai S, Koyama H (2003) Vaccine efficacy of a cell lysate with recombinant baculovirus-expressed feline infectious peritonitis (FIP) virus nucleocapsid protein against progression of FIP. *Veterinary Microbiology* 2, 31-44.
- Holliday TA (1971) Clinical aspects of some encephalopathies of domestic cats. *Veterinary Clinics North America, Small Animal Clinician* 1, 367-378.
- Holzworth JE (1963) Some important disorders of cats. *Cornell Veterinarian* 53, 157-160.
- Hoskins JD, Taylor HW, Lomax TL. (1994) Challenge trial of an intranasal feline infectious peritonitis vaccine. *Feline Practice* 22, 9-13.

Ishida T, Shibanaï A, Tanaka S, Uchida K, Mochizuki M. (2004) Use of recombinant feline interferon and glucocorticoid in the treatment of feline infectious peritonitis. *Journal of Feline Medicine Surgery* 6, 107-9.

Jacobse-Geels HE, Horzinek MC (1983) Expression of feline infectious peritonitis coronavirus antigens on the surface of feline macrophage-like cells. *Journal of General Virology* 64, 1859-66.

Juan-Sallés C, Domingo M, Herráez P, Fernández A, Segalés J, Fernández J (1998) Feline infectious peritonitis in servals (*Felis serval*). *Veterinary Record* 143, 535-36.

Kennedy MA, Abd-Eldaim M, Zika SE, Mankin JM, Kania SA. Evaluation of antibodies against feline coronavirus 7b protein for diagnosis of feline infectious peritonitis in cats. *Am J Vet Res.* 2008 Sep;69(9):1179-82.

Kiss I, Poland AM, Pedersen NC (2004) Disease outcome and cytokine responses in cats immunized with an avirulent feline infectious peritonitis virus (FIPV)-UCD1 and challenge-exposed with virulent FIPV-UCD8. *Journal of Feline Medicine Surgery* 6, 89-97.

Kiss I, Kecskeméti S, Tanyi J, Klingeborn B, Belák S (2000) Preliminary studies on feline coronavirus distribution in naturally and experimentally infected cats. *Research in Veterinary Science* 68, 237-42.

Kitagawa M, Okada M, Sato T, Kanayama K, Sakai T (2007) A feline case of isolated fourth ventricle with syringomyelia suspected to be related with feline infectious peritonitis. *Journal of Veterinary Medicine Science* 69, 759-62.

Klepfer S, Reed AP, Martinez M, Bhogal B, Jones E, Miller TJ (1995) Cloning and expression of FECV spike gene in vaccinia virus. Immunization with FECV S causes early death after FIPV challenge. *Advances Experimental Medicine Biology* 380, 235-41.

Kornegay JN (1978) Feline infectious peritonitis. *Journal American Animal Hospital Association* 14, 580-84.

Krum S et al (1975) Hydrocephalus associated with the nonexudative form of feline infectious peritonitis. *Journal American Veterinary Medical Association* 167, 746-48.

Kummrow M, Meli ML, Haessig M, Goenczi E, Poland A, Pedersen NC, Hofmann-Lehmann R, Lutz H (2005) Feline coronavirus serotypes 1 and 2: seroprevalence and association with disease in Switzerland. *Clinical and Diagnostic Laboratory Immunology* 12, 1209-15.

Kyuwa S, Tagawa Y, Shibata S, Doi K, Machii K, Iwakura Y (1998b) Murine coronavirus-induced subacute fatal peritonitis in C57BL/6 mice deficient in gamma interferon. *Journal Virology* 72, 9286-90.

Legendre AM and Whitenack DL (1975) Feline infectious peritonitis with spinal cord involvement in two cats. *Journal American Veterinary Medical Association* 167, 931-32.

MacEwen EG, Hurvitz AI (1977) Diagnosis and management of monoclonal gammopathies. *Veterinary Clinics North America* 7, 119-32.

Madewell BR, Crow SE, Nickerson TR (1978) Infectious peritonitis in a cat that subsequently developed a myeloproliferative disorder. *Journal American Veterinary Medical Association* 172, 169-72.

Marioni-Henry K, Vite CH, Newton AL, Van Winkle TJ (2004) Prevalence of diseases of the spinal cord of cats. *Journal Veterinary Internal Medicine* 18, 851-58.

Martin ML. 1985. Coronavirus enteritis and a recent outbreak following modified live virus vaccination. *Compendium Continuing Education Practicing Veterinarian*, 7(12), 1012-1017.

Martínez J, Ramis AJ, Reinacher M, Perpiñán D (2006) Detection of feline infectious peritonitis virus-like antigen in ferrets. *Veterinary Record* 158, 523.

McArdle F, Bennett M, Gaskell RM, Tennant B, Kelly DF, Gaskell CJ. (1992) Induction and enhancement of feline infectious peritonitis by canine coronavirus. *American Journal Veterinary Research* 53, 1500-06.

McKeirnan AJ et al (1981) Isolation of feline coronaviruses from two cats with diverse disease manifestations. *Feline Practice* 11, 16-20.

Meli M, Kipar A, Müller C, Jenal K, Gönczi E, Borel N, Gunn-Moore D, Chalmers S, Lin F, Reinacher M, Lutz H (2004) High viral loads despite absence of clinical and pathological findings in cats experimentally infected with feline coronavirus (FCoV) type I and in naturally FCoV-infected cats. *Journal Feline Medicine Surgery* 6, 69-81.

- Montali RJ and Strandberg JD (1972) Extraperitoneal lesions in feline infectious peritonitis. *Veterinary Pathology* 9, 109-21.
- Motokawa K, Hohdatsu T, Hashimoto H, Koyama H (1996) Comparison of the amino acid sequence and phylogenetic analysis of the peplomer, integral membrane and nucleocapsid proteins of feline, canine and porcine coronaviruses. *Microbiology and Immunology* 40, 425-33.
- Negrin A, Lamb CR, Cappello R, Cherubini GB (2007) Results of magnetic resonance imaging in 14 cats with meningoencephalitis. *Journal of Feline Medicine Surgery* 9, 109-16.
- Nichols PR, Morris DO, Beale KM. (2001) A retrospective study of canine and feline cutaneous vasculitis. *Veterinary Dermatology* 12, 255-64.
- Norris JM, Bosward KL, White JD, Baral RM, Catt MJ, Malik R. (2005) Clinicopathological findings associated with feline infectious peritonitis in Sydney, Australia: 42 cases (1990-2002). *Australian Veterinary Journal* 83, 666-73.
- Paltrinieri S (2008) The feline acute phase reaction. *Veterinary Journal* 177, 26-35.
- Paltrinieri S, Metzger C, Battilani M, , Gelain ME, Giordano A (2007) Serum alpha1-acid glycoprotein (AGP) concentration in non-symptomatic cats with feline coronavirus (FCoV) infection. *Journal Feline Medicine Surgery* 9, 271-77.
- Paltrinieri S, Grieco V, Comazzi S, Cammarata Parodi M (2001) Laboratory profiles in cats with different pathological and immunohistochemical findings due to feline infectious peritonitis (FIP). *Journal Feline Medicine Surgery* 3, 149-59.
- Paltrinieri S, Parodi MC, Cammarata G (1999) In vivo diagnosis of feline infectious peritonitis by comparison of protein content, cytology, and direct immunofluorescence test on peritoneal and pleural effusions. *Journal Veterinary Diagnostic Investigation* 11, 358-61.
- Paltrinieri S, Cammarata MP, Cammarata G, Comazzi S (1998) Some aspects of humoral and cellular immunity in naturally occurring feline infectious peritonitis. *Veterinary Immunology Immunopathology* 65, 205-20.
- Pedersen NC (1989) Animal virus infections that defy vaccination: Equine infectious anemia, caprine arthritis-encephalitis, maedi-visna, and feline infectious peritonitis. *Advances Veterinary Science Comparative Medicine* 33, 413-28.

Pedersen NC (1987a) Virologic and immunologic aspects of feline infectious peritonitis virus infection. *Advances Experimental Medicine Biology* 218, 529-50.

Pedersen NC (1987b) Basic and Clinical Immunology, In: Holzworth JE, *Diseases of the Cat*, WB Saunders Co, Philadelphia, pp146-181.

Pedersen NC (1983a) Feline infectious peritonitis and feline enteric coronavirus infections. Part I: Feline enteric coronavirus. *Feline Practice* 13, 13-19.

Pedersen NC (1983b) Feline infectious peritonitis and feline enteric coronavirus infections. Part II: Feline infectious peritonitis. *Feline Practice* 13, 5-19.

Pedersen NC (1976a) Feline infectious peritonitis. Something old, something new. *Feline Practice* 6, 42-51.

Pedersen NC (1976c) Serologic studies of naturally occurring feline infectious peritonitis. *American Journal Veterinary Research* 37, 1449-53.

Pedersen NC and Black JW (1983) Attempted immunization of cats against feline infectious peritonitis using either avirulent live virus or sublethal amounts of virulent virus. *American Journal Veterinary Research* 44, 229-34.

Pedersen NC and Floyd K (1985) Experimental studies with three new strains of feline infectious peritonitis virus FIPV-UCD2, FIPV-UCD3, and FIPV-UCD4. *Compendium Continuing Education Practicing Veterinarians* 7, 1001-11.

Pedersen NC, Allen CE, Lyons LA (2008). Pathogenesis of feline enteric coronavirus infection. *Journal Feline Medicine Surgery* 10, 529-541.

Pedersen NC, Sato R, Foley JE, Poland AM. (2004) Common virus infections in cats, before and after being placed in shelters, with emphasis on feline enteric coronavirus. *Journal Feline Medicine Surgery* 6, 83-88.

Pedersen NC, Addie D, Wolf A (1995) Recommendations from working group of the international coronavirus and feline infectious peritonitis workshop. *Feline Practice* 23(3), 108-111.

Pedersen NC, Boyle JF, Floyd K (1981a) Infection studies in kittens utilizing feline infectious peritonitis virus propagated in cell culture. *American Journal Veterinary Research* 42, 363-67.

Pedersen NC, Boyle JF, Floyd K, Fudge A, Barker J (1981b) An enteric coronavirus infection of cats and its relationship to feline infectious peritonitis. *American Journal Veterinary Research* 42, 368-77.

Pedersen NC, Ward J, Mengeling WL. (1978) Antigenic relationship of the feline infectious peritonitis virus to coronaviruses of other species. *Archives Virology* 58, 45-53.

Pedersen NC, Theilen G, Keane MA, Fairbanks L, Mason T, Orser B, Chen CH, Allison C (1977) Studies of Naturally Transmitted Feline Leukemia Virus Infection. *American Journal Veterinary Research* 38, 1523-31.

Peiffer RL Jr, Wilcock BP (1991) Histopathologic study of uveitis in cats: 139 cases (1978-1988). *Journal American Veterinary Medical Association* 198, 135-38.

Pesteanu-Somogyi LD, Radzai C, Pressler BM (2006) Prevalence of feline infectious peritonitis in specific cat breeds. *Journal Feline Medicine and Surgery* 8, 1-5.

Pfeifer ML, Evermann JF, Roelkie ME, Gallina AM, Ott RL, McKeirnan AJ (1983) Feline infectious peritonitis in a captive cheetah. *Journal American Veterinary Medical Association* 183, 1317-19.

Poelma FG, Peters JC, Mieog WHW, Zwart P. (1974) Infectie Peritonitiss bei Karakal (Felis caracal) and Nordluchs (Felis lynx lynx). *Proceedings Erkrankungen der Zootiere, 13th International Symposium of Zoo Veterinarians, Helsinki, Finland*, pp 249-53.

Poland AM, Vennema H, Foley JE, Pedersen NC (1996) Two related strains of feline infectious peritonitis virus isolated from immunocompromised cats infected with a feline enteric coronavirus. *Journal Clinical Microbiology* 34, 3180-84.

Postorino-Reeves N, Coyne MJ, Herman JG (1992) Evaluation of the field efficacy of Primicell-FIP vaccine. *Feline Health Topics* 7, 6-8.

Potkay S, Bacher JD, Pitts TW (1974) Feline infectious peritonitis in a closed breeding colony. *Laboratory Animal Science* 24, 279-89.

- Pratelli A. Comparison of serologic techniques for the detection of antibodies against feline coronaviruses. *Journal Veterinary Diagnostic Investigation*. 2008 Jan;20(1):45-50.
- Quesnel AD, Parent JM, McDonnell W, Percy D, Lumsden JH (1997) Diagnostic evaluation of cats with seizure disorders: 30 cases (1991-1993). *Journal American Veterinary Medicine Association* 210, 65-71.
- Rand JS, Parent J, Percy D, Jacobs R. (1994) Clinical, cerebrospinal fluid, and histological data from twenty-seven cats with primary inflammatory disease of the central nervous system. *Canadian Veterinary Journal* 35, 103-10.
- Reeves NC, Pollock RV, Thurber ET (1992) Long-term follow-up study of cats vaccinated with a temperature-sensitive feline infectious peritonitis vaccine. *The Cornell Veterinarian* 82, 117-23.
- Ritz S, Egberink H, Hartmann K (2007) Effect of feline interferon-omega on the survival time and quality of life of cats with feline infectious peritonitis. *Journal Veterinary Internal Medicine* 21, 1193-97.
- Rohrbach BW, Legendre AM, Baldwin CA, Lein DH, Reed WM, Wilson RB (2001) Epidemiology of feline infectious peritonitis among cats examined at veterinary medical teaching hospitals. *Journal American Veterinary Medical Association* 218, 1111-15.
- Rota A, Paltrinieri S, Jussich S, Ubertalli G, Appino S (2007) Priapism in a castrated cat associated with feline infectious peritonitis. *Journal Feline Medicine Surgery* [Epub ahead of print].
- Rottier PJ, Nakamura K, Schellen P, Volders H, Haijema BJ (2005) Acquisition of macrophage tropism during the pathogenesis of feline infectious peritonitis is determined by mutations in the feline coronavirus spike protein. *Journal Virology* 79, 14122-130.
- Saverio P, Alessia G, Vito T, Stefano (2007) Critical assessment of the diagnostic value of feline alpha1-acid glycoprotein for feline infectious peritonitis using the likelihood ratios approach. *Journal Veterinary Diagnostic Investigation* 19, 266-72.
- Sigurdardóttir OG, Kolbjørnsen O, Lutz H (2001) Orchitis in a cat associated with coronavirus infection. *Journal Comparative Pathology* 124, 219-22.

Simons AF, Vennema H, Rofina JE, Pol JM, Horzinek MC, Rottier PJM, Egberink HF (2005) A mRNA PCR for the diagnosis of feline infectious peritonitis. *Journal Virological Methods* 124, 111-16.

Singh M, Foster DJ, Child G, Lamb WA. (2005) Inflammatory cerebrospinal fluid analysis in cats: clinical diagnosis and outcome. *Journal Feline Medicine Surgery* 7, 77-93.

Slausen DO and Finn JP (1972) Meningoencephalitis and panophthalmitis in feline infectious peritonitis. *Journal American Veterinary Medical Association* 160, 729-34.

Sparkes AH, Gruffydd-Jones TJ, Harbour DA (1991) Feline infectious peritonitis: a review of clinicopathological changes in 65 cases, and a critical assessment of their diagnostic value. *Veterinary Record* 129, 209-12.

Steinberg TA, Boettcher IC, Matiasek K, Hirschvogel K, Hartmann K, Fischer A, Kuntz A (2008) Use of albumin quotient and IgG index to differentiate blood- vs brain-derived proteins in the cerebrospinal fluid of cats with feline infectious peritonitis. *Veterinary Clinical Pathology* 37, 207-16.

Stoddart CA, Barlough JE, Baldwin CA, Scott FW (1988) Attempted immunisation of cats against feline infectious peritonitis using canine coronavirus. *Research Veterinary Science* 45 383-88.

Tammer R, Evensen O, Lutz H, Reinacher M (1995) Immunohistological demonstration of feline infectious peritonitis virus antigen in paraffin-embedded tissues using feline ascites or murine monoclonal antibodies. *Veterinary Immunology and Immunopathology* 49, 177-82.

Theobald J, in Fowler ME (1978) *Zoo and Wild Animal Medicine*. WB Saunders Co., Philadelphia, pp 650-67.

Timmann D, Cizinauskas S, Tomek A, Doherr M, Vandeveld M, Jaggy A (2008) Retrospective analysis of seizures associated with feline infectious peritonitis in cats. *Journal Feline Medicine Surgery* 10, 9-15.

Toomey JM, Carlisle-Nowak MM, Barr SC, Lopez JW, French TW, Scott FW, Hoose W, Pizano S, Dubey JP (1995) Concurrent toxoplasmosis and feline infectious peritonitis in a cat. *Journal American Animal Hospital Association* 31, 425-58.

- Trotman TK, Mauldin E, Hoffmann V, Del Piero F, Hess RS (2007) Skin fragility syndrome in a cat with feline infectious peritonitis and hepatic lipidosis. *Veterinary Dermatology* 18, 365-69.
- Tuch K, Witte KH, Wüller H (1974) Feststellung der felinen infektiösen Peritonitis (FIP) bei Hauskatzen and Leoparden in Deutschland. *Zentralblatt Veterinärmedizin B* 21, 426-41.
- Van Kruiningen (1983) The classification of feline colitis. *Journal Comparative Pathology* 93, 275-94.
- Vennema H, Poland A, Foley J, Pedersen NC (1998) Feline infectious peritonitis viruses arise by mutation from endemic feline enteric coronaviruses *Virology* 243, 150-57.
- Vennema H, de Groot RJ, Harbour DA, Horzinek MC, Spaan WJ (1990) Early death after feline infectious peritonitis virus challenge due to recombinant vaccinia virus immunization. *Journal Virology* 64, 1407-09.
- Ward BC and Pedersen NC (1966) Infectious Peritonitis in Cats. *Journal American Veterinary Medical Association* 154, 26-35.
- Ward J (1970) Morphogenesis of a virus in cats with experimental feline infectious peritonitis. *Virology* 41, 191-94.
- Wasmoen TL, Kadakia NP, Unfer RC, Fickbohm BL, Cook CP, Chu HJ, Acree WM (1995) Protection of cats from infectious peritonitis by vaccination with a recombinant raccoon poxvirus expressing the nucleocapsid gene of feline infectious peritonitis virus. *Advances Experimental Medicine and Biology* 380, 221-28.
- Watt NJ, MacIntyre NJ, McOrist S (1993) An extended outbreak of infectious peritonitis in a closed colony of European wildcats (*Felis sylvestris*). *Journal Comparative Pathology* 108, 73-9.
- Weijer K, UijtdeHaag F, Osterhaus A (1986) Control of feline leukaemia virus by a removal programme. *Veterinary Record* 119, 555-6.
- Weiss RC, Toivio-Kinnucan M (1988) Inhibition of feline infectious peritonitis virus replication by recombinant human leukocyte (alpha) interferon and feline fibroblastic (beta) interferon. *American Journal Veterinary Research* 49, 1329-35.

Weiss RC, Cox NR, Martinez ML (1993) Evaluation of free or liposome-encapsulated ribavirin for antiviral therapy of experimentally induced feline infectious peritonitis. *Research Veterinary Science* 55, 162-72.

Wesley RD. The S gene of canine coronavirus, UCD-1, is more closely related to the S gene of transmissible gastroenteritis virus than to that of feline infectious peritonitis virus. *Virus Research* 61, 145-52.

Wolf AM (1997) Feline infectious peritonitis, part 2. *Feline Practice* 25(3), 24-28.

Wolfe LG and Griesemer RA (1966) Feline infectious peritonitis. *Pathologica Veterinaria* 3, 255-270.

Woods RD (1984) Efficacy of vaccination of sows with serologically related coronaviruses for control of transmissible gastroenteritis in nursing pigs. *American Journal Veterinary Research* 45, 1726-9.

Woods RD and Pedersen NC (1979) Cross-protection studies between feline infectious peritonitis and porcine transmissible gastroenteritis viruses. *Veterinary Microbiology* 4, 11-16.

Wright KN, Gompf RE, DeNovo RC Jr (1999) Peritoneal effusion in cats: 65 cases (1981-1997). *Journal of American Veterinary Medical Association* 214, 375-81.

Zabel P, Schade FU, Schlaak M (1993) Inhibition of endogenous TNF formation by pentoxifylline. *Immunobiology* 187, 447-6

Zook BC, King NW, Robinson RL, McCombs HL (1968) Ultrastructural evidence for the viral etiology of feline infectious peritonitis. *Pathologica Veterinaria* 5, 91-95.